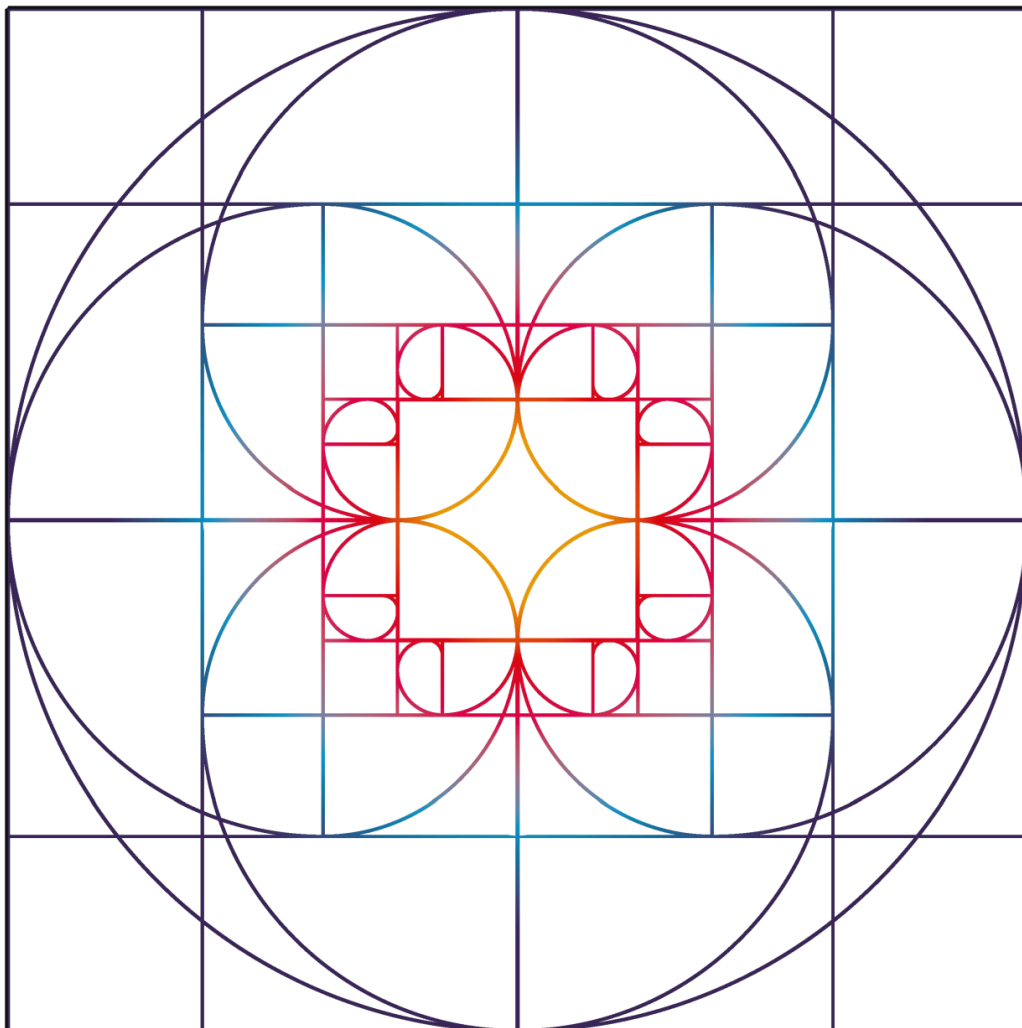


F. K. Dzalaeva

FUNCTION AND AESTHETIC.  
TREATMENT OF PATIENTS  
WITH FULL MONTH  
REHABILITATION.

Part 4



F. K. Dzalaeva

**Function and Aesthetic.  
Treatment of patients with  
full month rehabilitation.  
Part 4**

Electronic publication

Saint Petersburg  
Naukoemkieologii  
2023

ISBN 978-5-907618-56-5  
© Dzalaeva F.K., 2023

UDC 616.314

LBC 56.6

Reviewers:

*Antonik M. M.* – Doctor of Medical Sciences, Associate Professor of the Moscow State Medical and Dental University named after A.I. Evdokimov of the Ministry of Health of Russia;

*Chikunov S. O.* – Doctor of Medical Sciences, Professor of the Peoples' Friendship University of Russia, Department of Orthopedic Dentistry

Dzalaeva, F. K.

Function and Aesthetic. Treatment of patients with full month rehabilitation. Part 4 [Electronic resource] / F. K. Dzalaeva. – Saint Petersburg, Naukoemkie technologii, 2023 – 55. – URL:

<https://publishing.intelgr.com/archive/Function-and-Aesthetic-4.pdf>

ISBN 978-5-907618-56-5

For dentists of all profiles, teachers of dental school and Universities, postgraduate students, practical dentists, practical dental technicians and doctors.

**Dzalaeva** Fatima Kazbekovna

Function and Aesthetic.

Treatment of patients with full month rehabilitation.

Part 4

Electronic publication

Editor V.S. Kuznetsova

Signed for use on 17.04.2023.

The edition volume 5.1 MB

Naukoemkie technologii, Publishing House

Intel Group Corporation, Ltd.

website: <https://publishing.intelgr.com>

E-mail: [publishing@intelgr.com](mailto:publishing@intelgr.com)

Tel.: +7 (812) 945-50-63

ISBN 978-5-907618-56-5

© Dzalaeva F.K., 2023

© Layout. Kuznetsova V.S., 2023

## Contents

<b>Clinical Case #1</b> .....	4
After condylography.....	8
Cephalometric analyses .....	9
Slavicek Interactive Verbal Analysis .....	10
Condylography .....	11
Esthetic Analyses.....	15
Treatment plan.....	18
Casts mounted in articulator.....	18
Teeth preparation.....	21
Photos of models and silicone keys.....	22
Results: Final dental restorations .....	26
Before January 2023.....	27
After March 2023 .....	27
<b>Clinical Case #2</b> .....	28
Lateral X ray after comdylography .....	32
Cephalometric analyses .....	33
Slavicek Interactive Verbal Analysis .....	34
Articulator settings .....	35
Esthetic analyses.....	36
Face Profile.....	36
Casts in RP .....	46
Casts with Wax-up .....	47
Printed casts with digital wax up.....	48
RP .....	50
Mock-up march 2023 .....	52
Canine guidance march 2023 .....	53
Teeth Preparation March 2023 .....	54
Results: Final dental restorations .....	54
Before / After.....	55

## Clinical Case #1

Patient: male.

Date of birth 24.01.2003.

Date of examination 25.01.2023.

Chief complaint: grinding of the teeth.

Midline shifted to the right.

Skeletal class I tends to II.

Intraoral pictures April 2022.

Table #1

Special Medical Analysis			
Do you have or did ever have an illness with regard to point 1-12?			
		Yes	No
1.	Infections		X
2.	Cardo-vascular systems		X
3.	Respiratory system		X
4.	Digestive system		X
5.	Metabolic system		X
6.	Allergies		X
7.	Urogenital problems		X
8.	Central nervous system		X
9.	Psychological problems (therapy)		X
10.	Rheumatic disease		X
11.	Hormonal disease		X
12.	Special problems		X
Main concern: esthetic, low chewing efficacy			

Dental History Analysis		Valuation	Yes	No		
1.	Do you have problems when you chew?	1	X			
2.	Do you have problems when you are talking?			X		
3.	Do you have problems in closing your teeth property?			X		
4.	Are any of your teeth especially sensitive?			X		
5.	Do you have problem when you open your mouth very wide?			X		
6.	Do your jaw joints make noise and if so, on what side?			X		
7.	Do you have pain in the area of your jaw joints?			X		
8.	Do you suffer from headaches?	1		X		
9.	Do you suffer from cramps or spasm in your head, neck or throat?			X		
10.	Do you have in general problems with your posture?	1		X		
	Occlusal Index	1.00				
11.	Have you ever had serious accident?			X		
12.	Did you have one or more oral intubations?			X		
13.	Have you ever had orthodontic treatment or ...			X		
14.	Have you had a treatment with splint?			X		
15.	Are you grinding or pressing with your teeth?			X		
16.	Do you think that treatment is necessary?		X			
17.	Do you think that there is a serious disorder or illness?			X		
18.	When the last time you had dental treatment and what was done?					
	How would you describe your psychic behavior?					
	happy	sad	calm	excited	self-controlled	lack of self-control
19.	X					

Table #2

Muscle Diagnosis		Right		Left	
		+	++	+	++
1.	Shoulders and neck	X		X	
2.	Atlanto-occipital region	X		X	
3.a	M.temporalis ant.				
3.b	M.temporalis med.				
3.c	M.temporalis post.				
4.a	M.masseter (superficial)				
4.b	M.masseter (deep)				
5.	Tuber maxillae				
6.	M.pterygoideus medialis	X			
7.	M.mylohyideus				
8.	M.digastricus				
9.	Suprahyoidale M.				
10.	Infrahyoidale M.				
11.	Larynx				
12.	M.sterno-cleido-mastoideus				
13.	M.omohyoideus			X	
14.	Tongue				
15.	Comparative palpation of jawjoints*				
	a) Lateral poles, statically				
	b) Lateral poles, in rotation				
	c) Retral joint space				
	d) Lig.temporo-mandibulare				

### Movement Muscles.

Posture 1, 2, 7, 12, 13, 14.

Closing 3a, 3b, 4a, 4b, 5.

Opening/ Protraction 8, 9, 10.

Retraction 3c, 8.

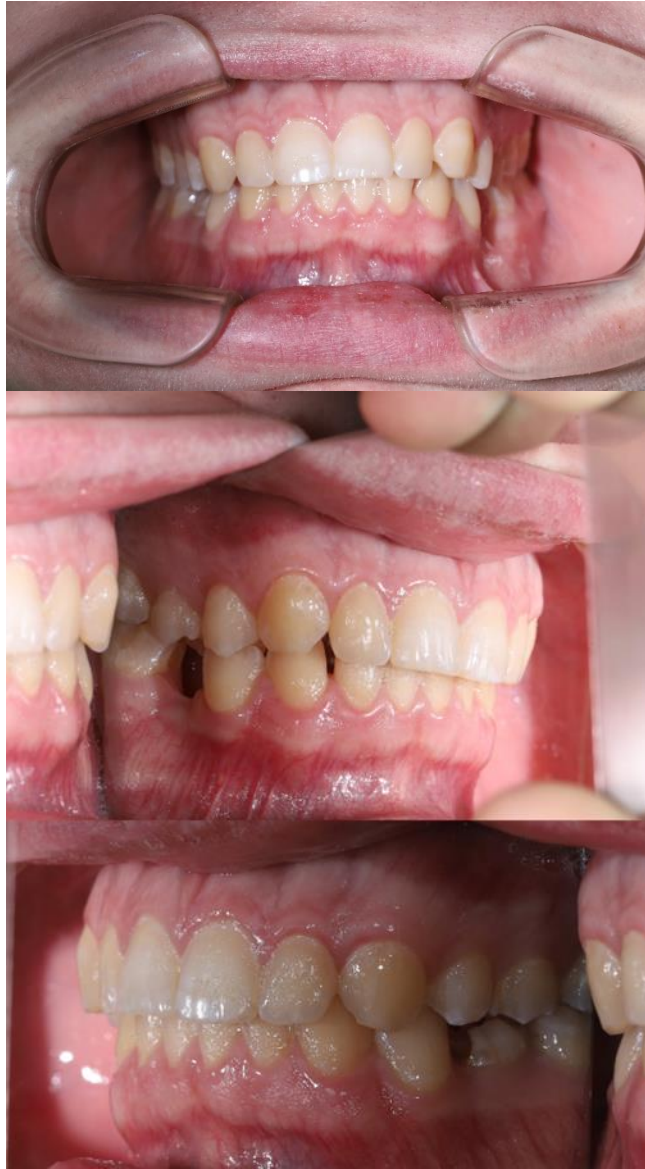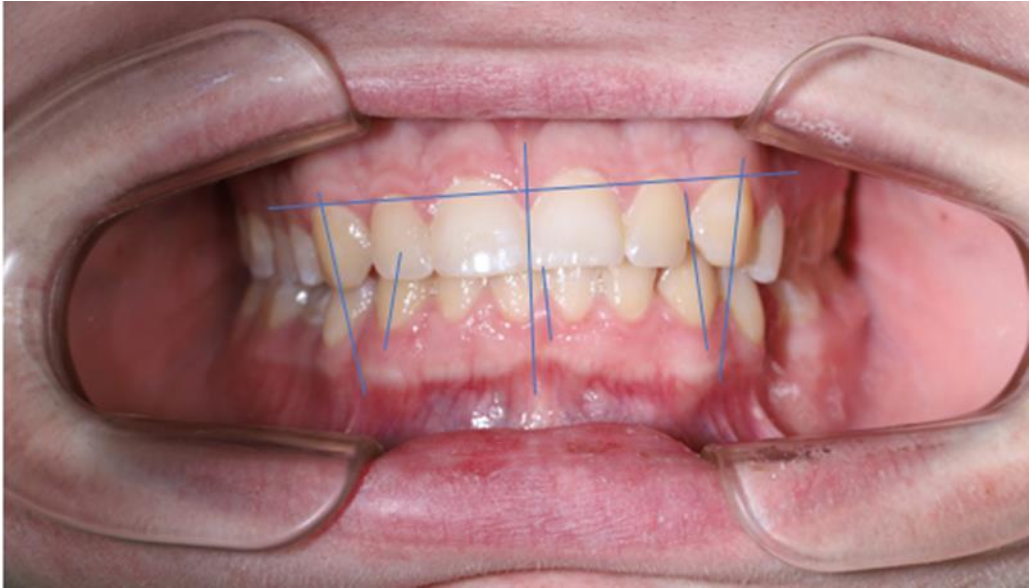
Medio / Laterotrraction 6, 3a, 4a.

Hyoid-Position 8, 9, 10, 11, 13.

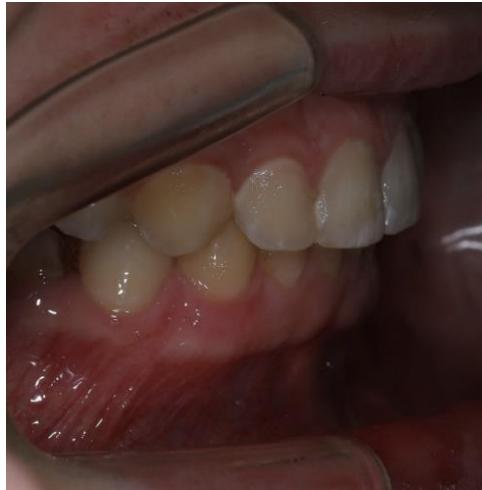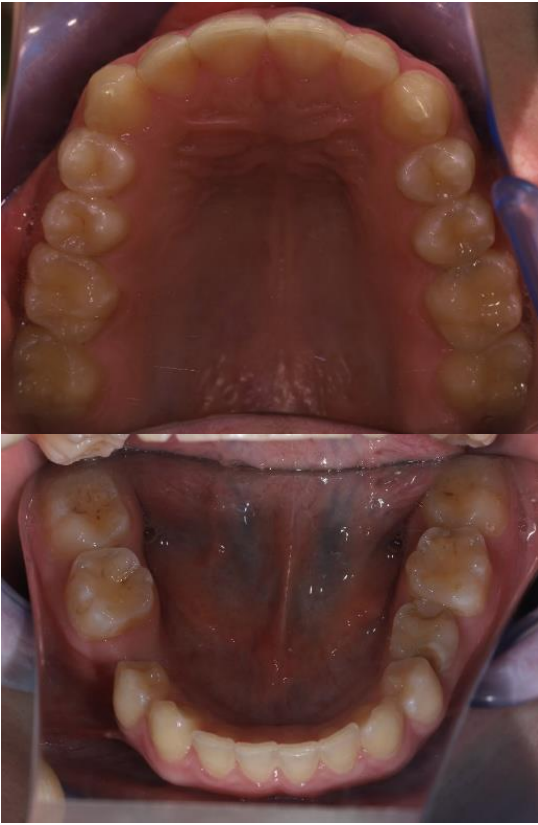Functions 7, 8, 9, 10, 11, 14.

TMJ 15a, 15b, 15c, 15d.

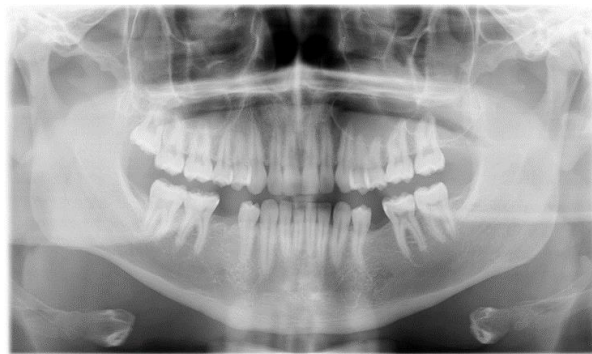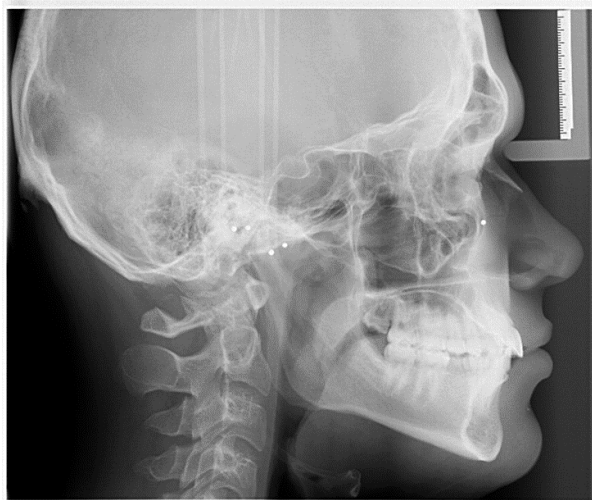
Intraoral pictures February, 2023







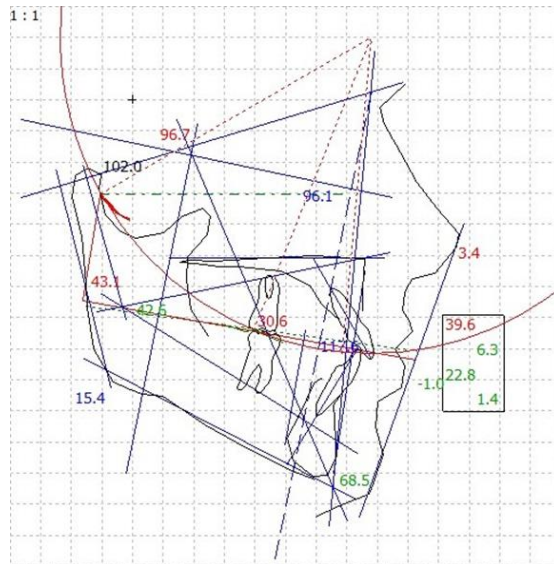
**After condylography**



# Cephalometric analyses

Table #3

Slavicek Analysis			
Skeletal Measurement	Norm	Value	Trend
Facial Axis	90.0°	96.7	2B***
Facial Depth	91.5°	96.1	1+*
Mandibular Plane	21.5°	15.4	1B*
Facial Taper	68.0°	68.4	
Mandibular Arc	31.2°	43.1	2B**
Maxillary Position	65.0°	68.6	1+*
Convexity	-1.00 mm	3.3	2X**
Lower Facial Height (by R. Slavicek)	45.2°	42.5	
Lower Facial Height to Point D	51.7°	46.3	
Dental Measurement	Norm	Value	Trend
Interincisal Angle	132.8°	117.5	1-*
Upper Incisor Protrusion	4.3 mm	6.2	
Upper Incisor Inclination	23.1°	39.6	2+**
Upper Incisor Vertical	mm	2.1	
Lower Incisor Protrusion	1.2 mm	1.3	
Lower Incisor Inclination	24.1°	22.8	
Upper Molar Position	21.0 mm	30.5	4+***>
Occlusal Plane	Norm	Value	Trend
Occlusal Plane – Axis Orbital Plane (Slavicek)	----°	9.9	
Idealized Occlusal Plane – Axis Orbital Plane	----°	8.5	
Distance Occlusal Plane – Axis (DPO)	40.9 mm	34.7	
Radius of Curve of Spee	---- mm	101.9	
Lip Embrasure	0.0 mm	-2.4	
Occlusal Plane Xi Distance	-1.4 mm	-0.2	
Functional Measurement	Norm	Value	Trend
Horizontal Condylar Inclination right	----°	46.4	
Horizontal Condylar Inclination left	----°	51.0	
Horizontal Condylar Inclination	----°	48.7	
Relative Condylar Inclination	----°	38.7	
Relative Condylar Inclination 6	----°	28.1	
Relative Condylar Inclination 7	----°	30.9	
Relative Condylar Inclination 8	----°		
Anterior Guidance (S-AOP)	°		
Relative Anterior Guidance	°		
Esthetic Measurement (Lip Relation)	Norm	Value	Trend
Esthetic Plane	-2.9 mm	-1.0	



### **Important**

OPI R = 11° degrees.

OPI L = 11° degrees.

SCI R = 52° degrees.

SCI L = 52° degrees.

Anterior Guidance 60° degrees.

DOA R= 11° degrees.

DOA L= 11° degrees.

Maxilla position – prognathic.

Mandible position – neutral.

Skeletal class is I with tends to III.

### **Slavicek Interactive Verbal Analysis**

The skeletal trend of the mandible is strongly brachyfacial.

Skeletal class is I with tend to II.

The maxilla is positioned strongly prognathic.

The mandible is positioned prognathic with tendency to neutral.

The lower facial height is normal.

Dental class unknown.

The protrusion of the upper incisor is normal.

The inclination of the upper is strongly increased.

The protrusion of the lower incisor is normal.

The inclination of the lower incisor is normal.

The interincisal angle is diminished.

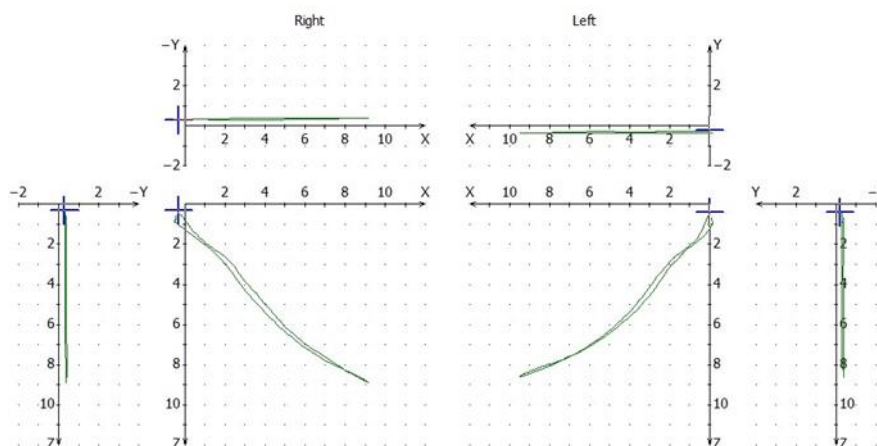
Occlusal concept: group function.

Table #4

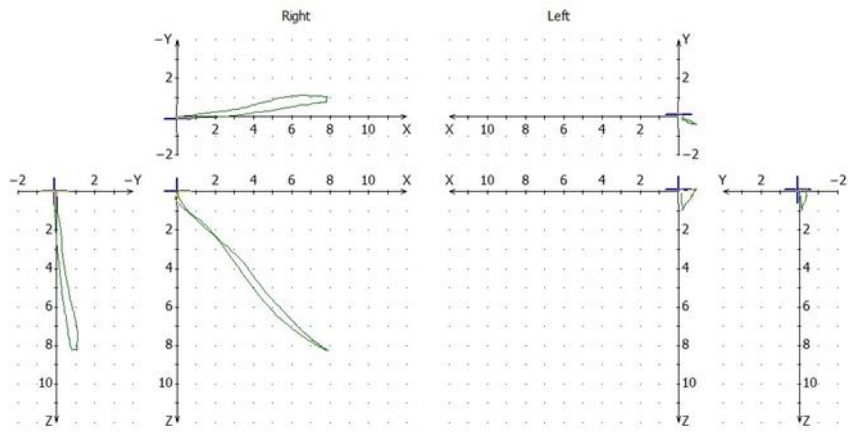
Determinants	Norm	Value	Trend
Facial Axis	90.0°	96.7	2B**
Facial Depth	89.0°	96.1	1+*
Facial Taper	68.0°	68.4	
Mandibular Plane	24.0°	15.4	1B*
Related Values	Norm	Value	Trend
Bjoerk Sum	396.0°	387.6	3-***
Facial Length Ratio	63.5%	69.3	2+***
Y Axis to S N	67.0°	64.2	
Y Axis (Downs)	61.2°	50.5	3-***
S N to Gonion Gnathion Angle	32.6°	27.6	1-*

## Condylography

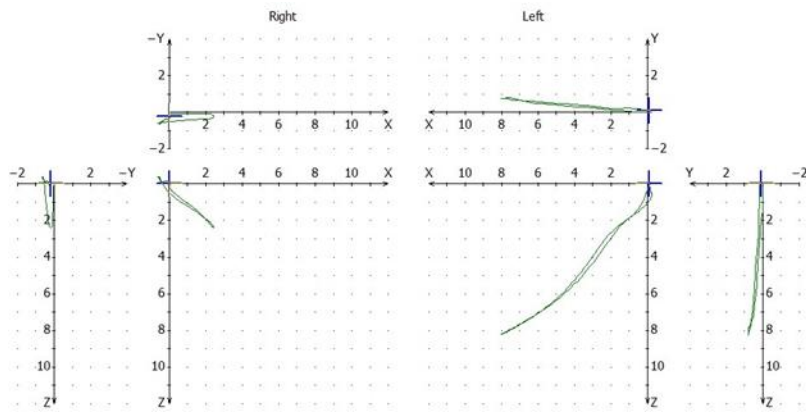
Protrusion / Retrusion / Deviation to the left



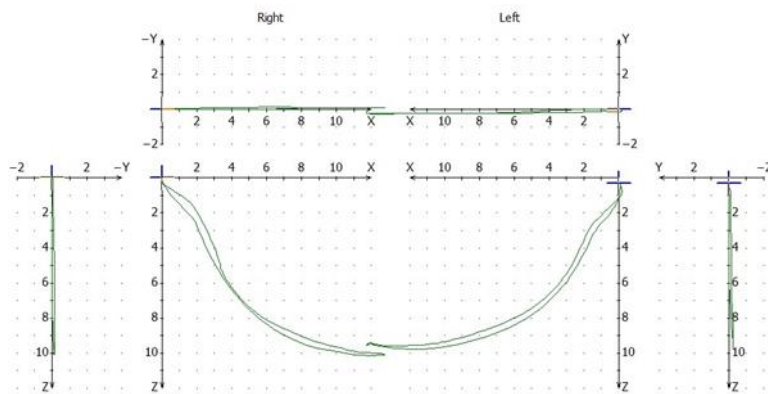
Mediotrusion (right)



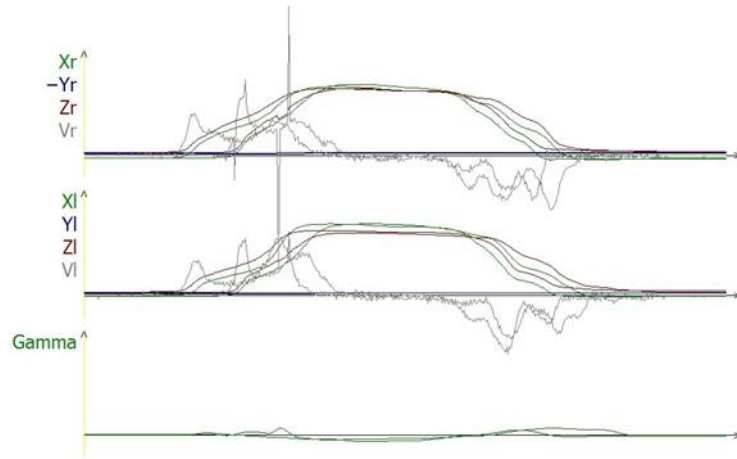
Mediotrusion (left)



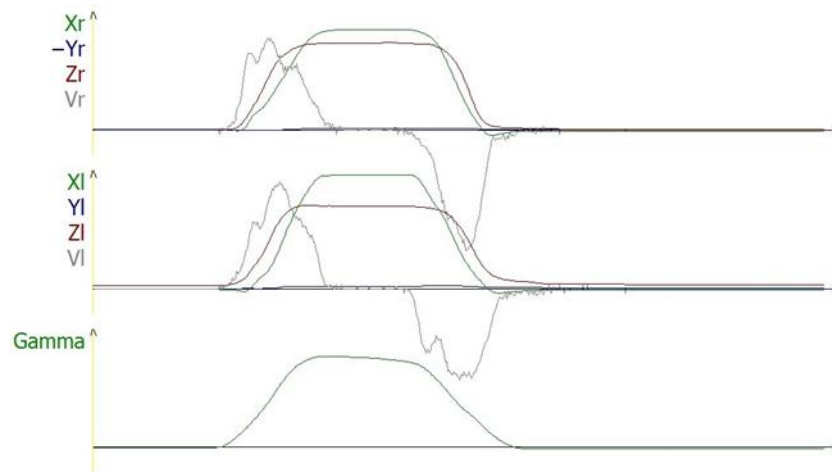
Open-close



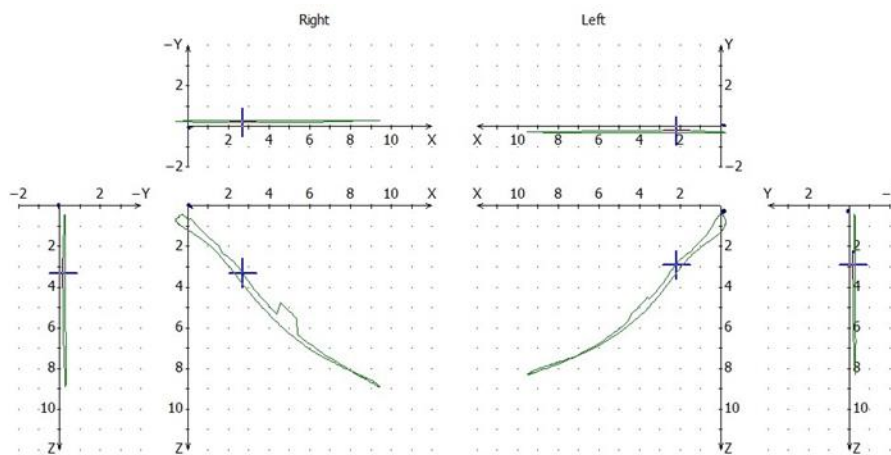
## Protrusion time curve



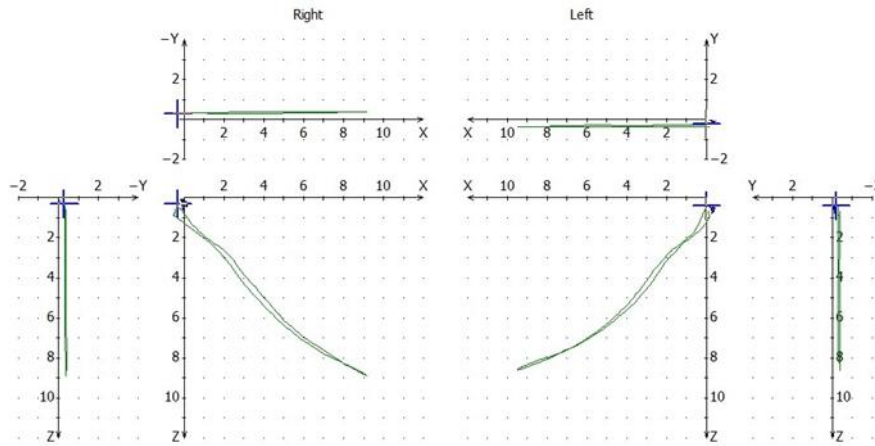
## Open time curve – Muscle tension



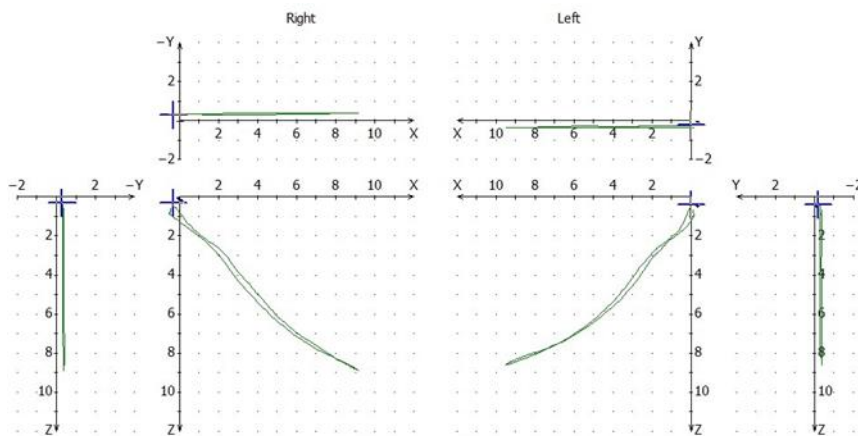
## Bruxism – Resurtrusion



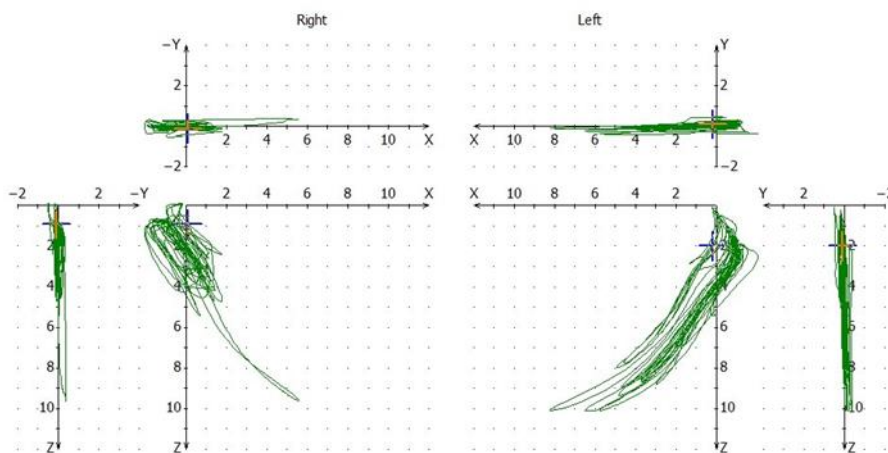
## Speech 50-60 and Protrusion / Redetrusion on the left side



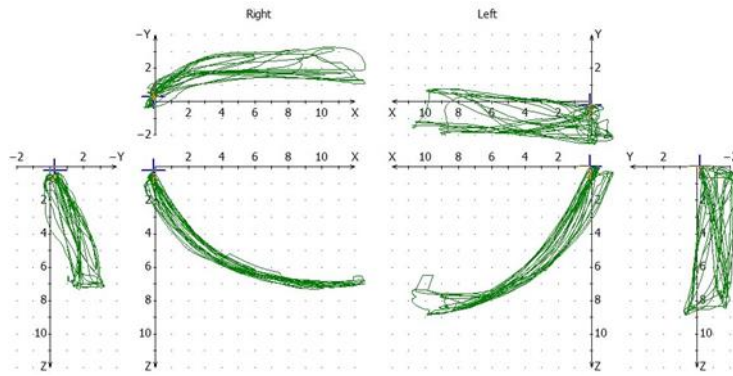
## Speech 60-70 and Protrusion. Surtrusion on the right side.



## Mastication



# Free movement



# Esthetic Analyses

3.3 Interincisal line evaluation

Interincisal line inclination: Right inclination, Vertical, Left inclination

Interincisal line vs upper lip philtrum: Deviated right, Centered, Deviated left

Within 4 mm, > 4 mm

3.4 Occlusal plane orientation & Incisal edge position

Occlusal Plane Orientation: Right inclination, Left inclination, Ideal

Incisal Edge Position: Flat, Reverse, Convex

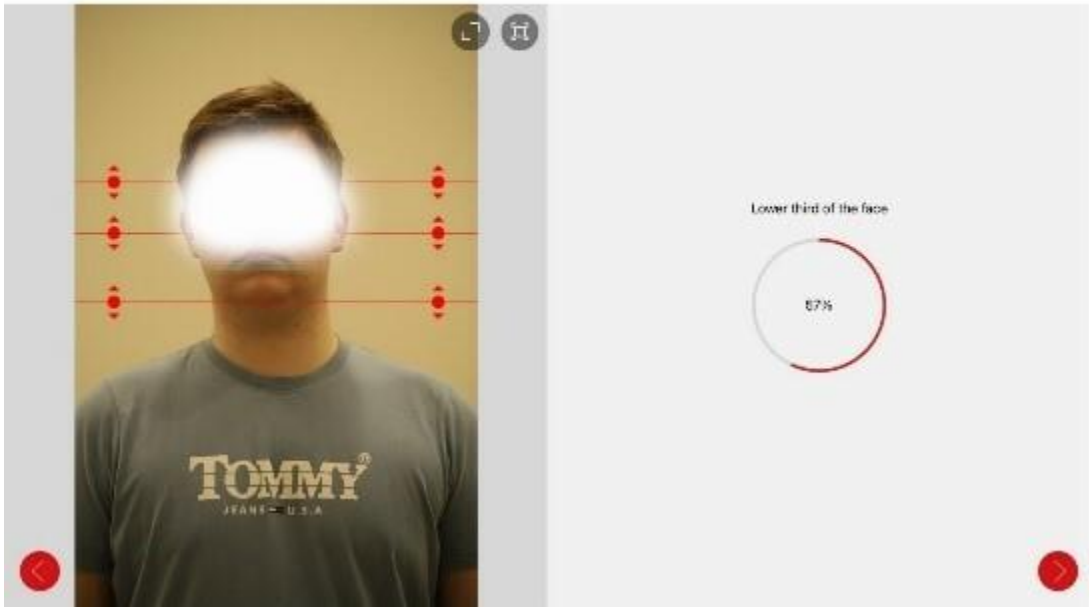


6  
FACE DATA  
PROCESSING

6.1  
Facial proportions

7  
DENTO-LABIAL  
PROCESSING

8  
DENTO-LABIAL  
PROCESSING

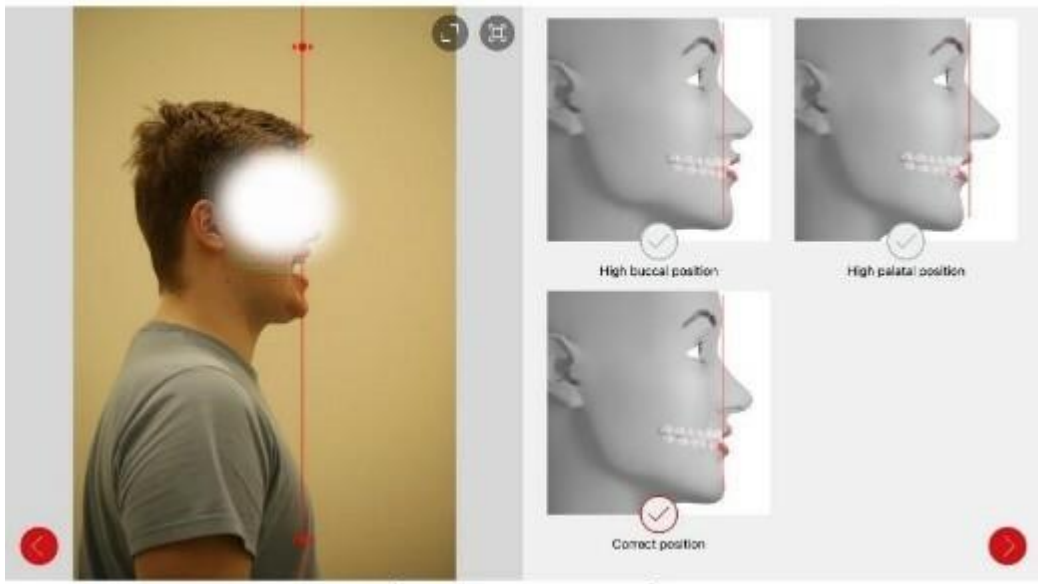


6  
FACE DATA  
PROCESSING

6.3  
Skeletal evaluation of tooth position

7  
DENTO-LABIAL  
PROCESSING

8  
DENTO-LABIAL  
PROCESSING

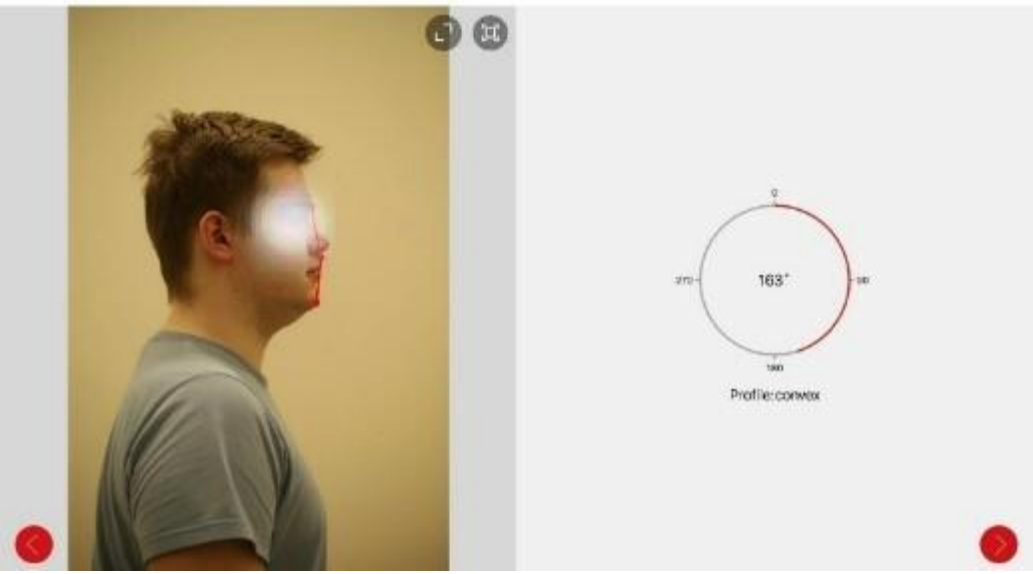


6  
FACE DATA  
PROCESSING

6.2  
Profile

7  
DENTO-LABIAL  
PROCESSING

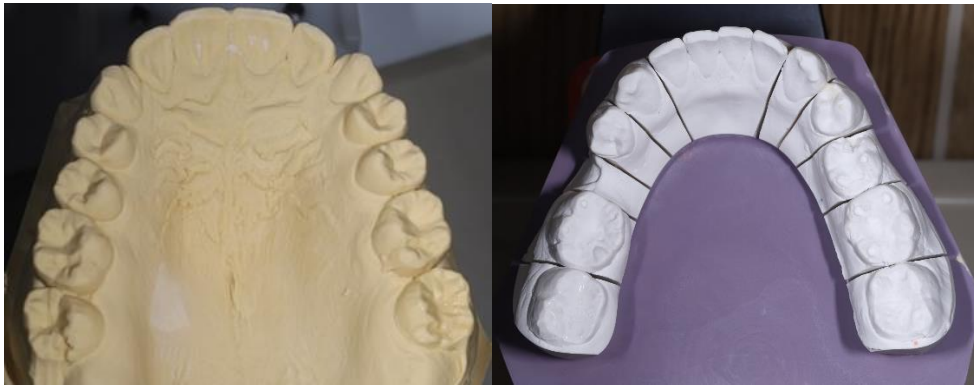
8  
DENTO-LABIAL  
PROCESSING




## Treatment plan

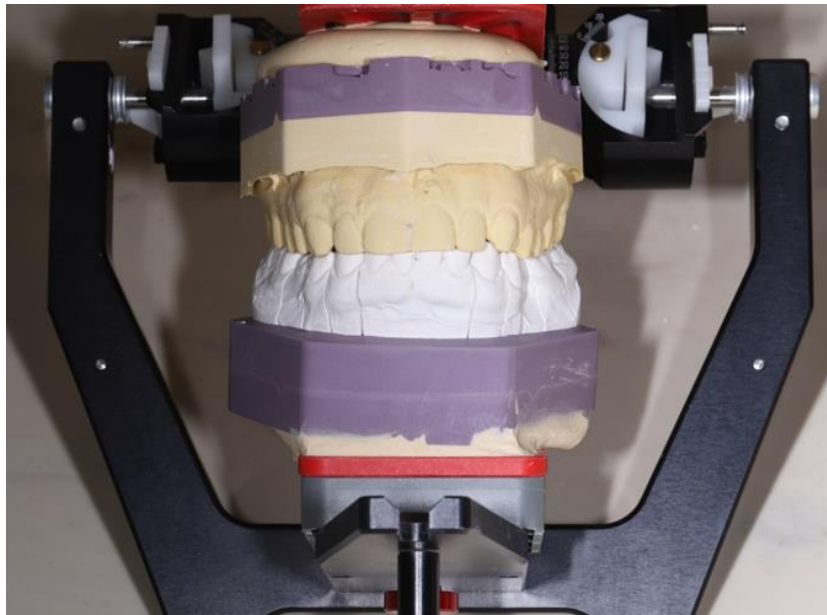1. Wax-up.
2. Long time temporaries.
3. Final restorations.

## Casts mounted in articulator

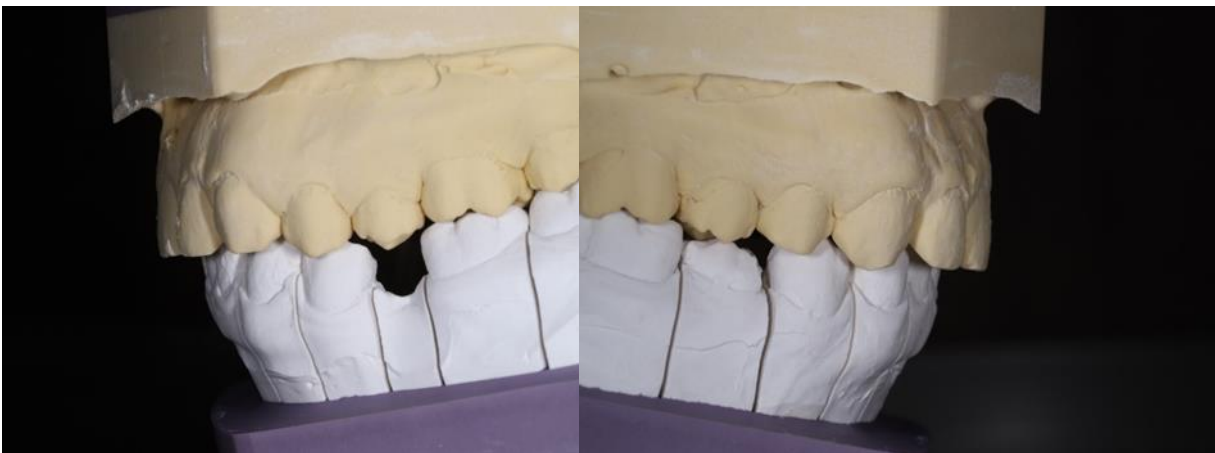

## Anterior Guidance

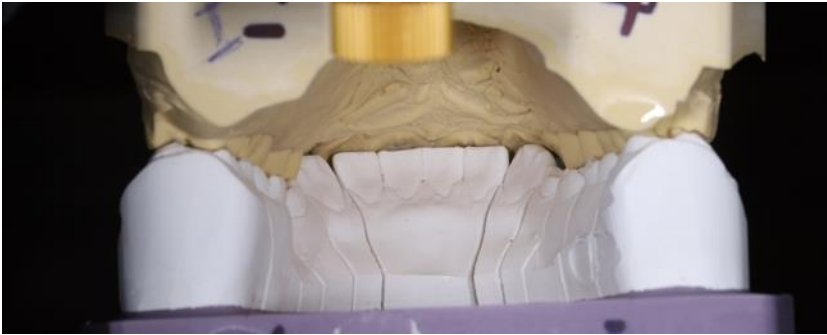




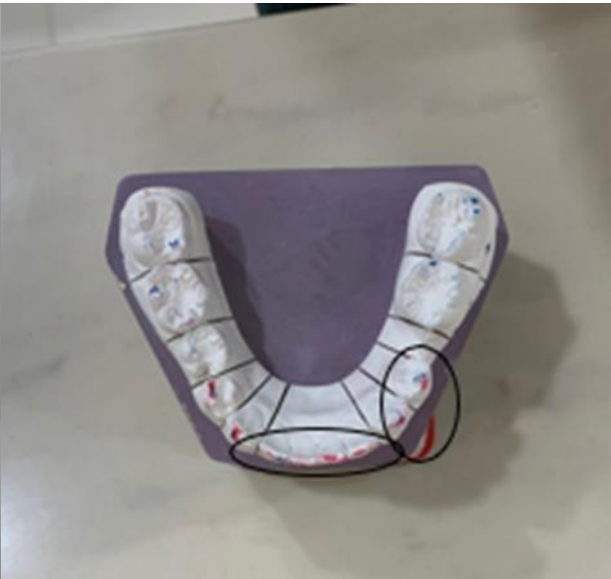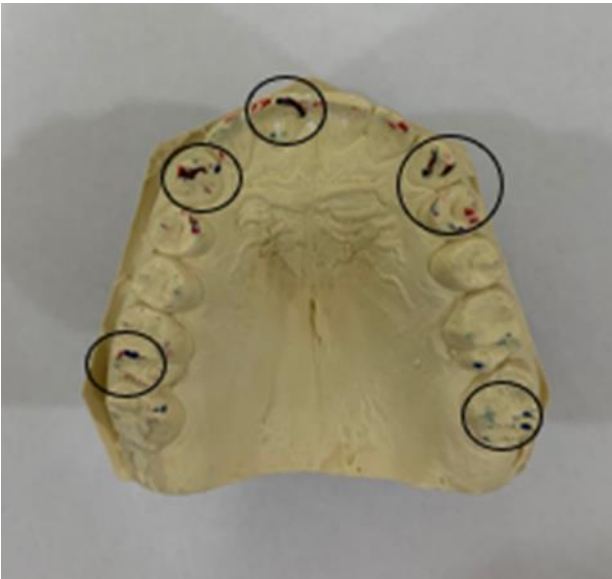Overerupted tooth 2.5. Deciduous molar on the lower jaw.



Posterior OPI steps



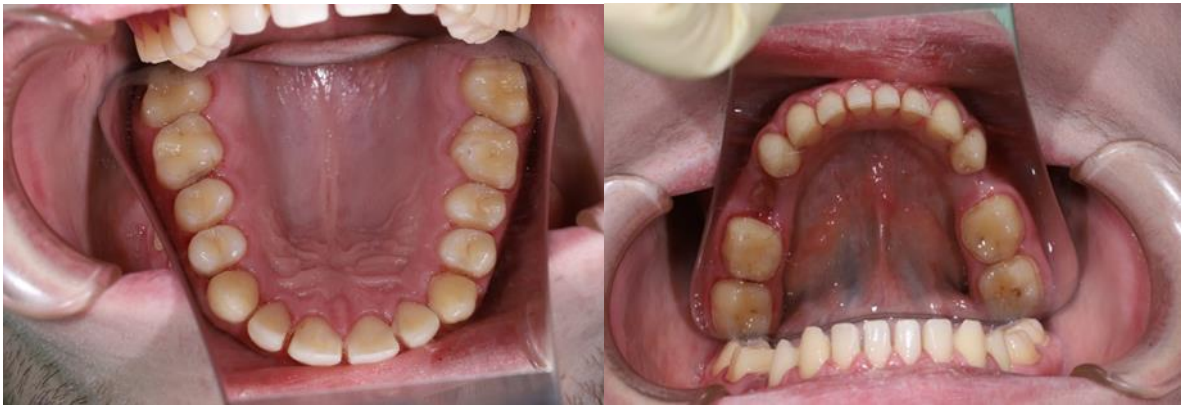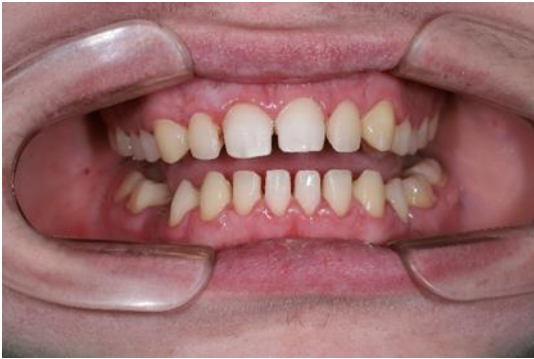AG and Canine control in articulator.



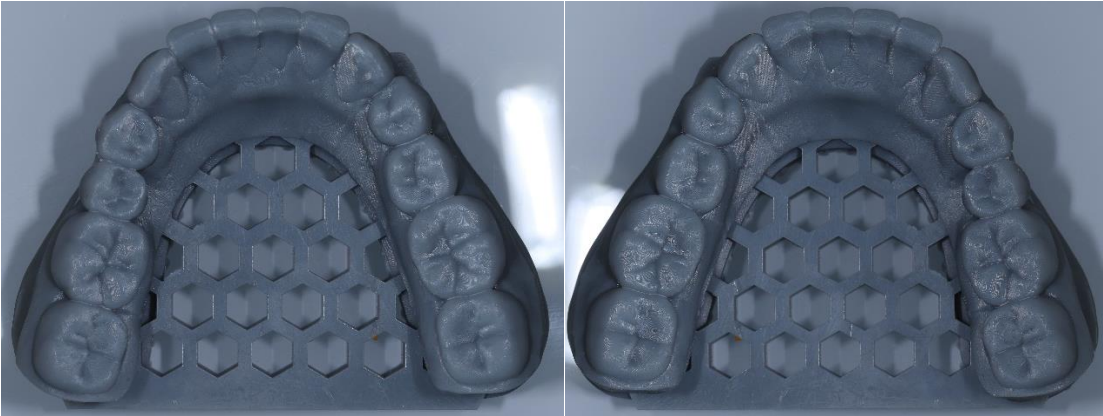
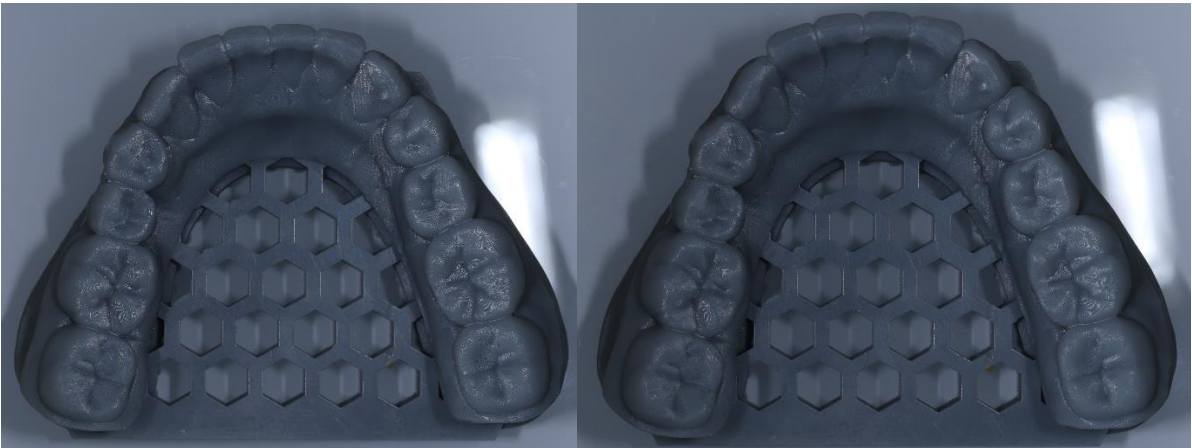
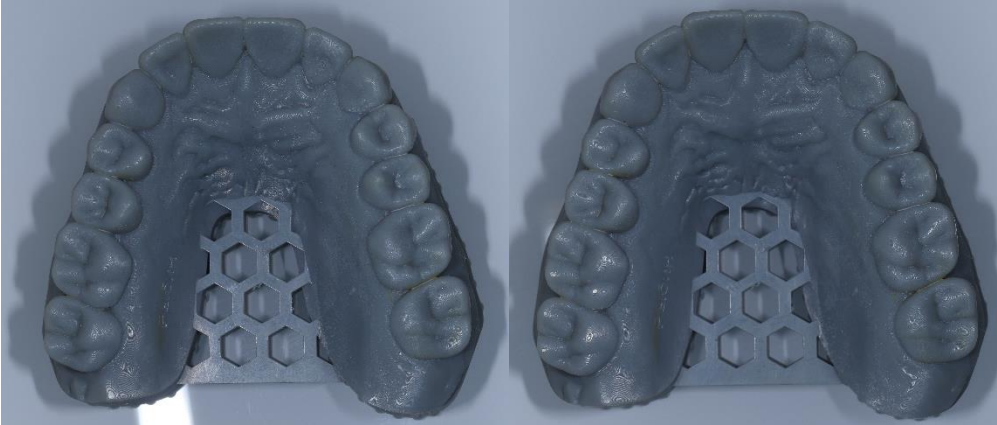OPI R = 9, OPI L = 8.

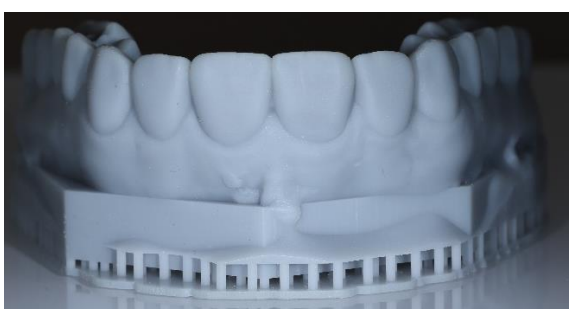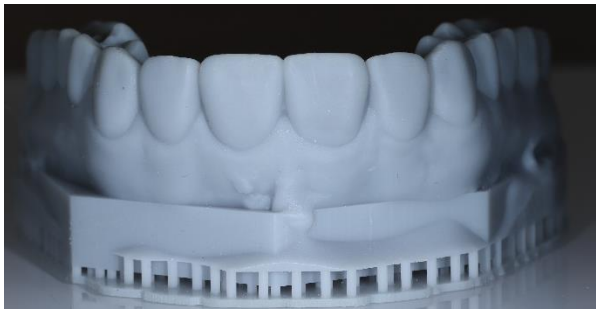

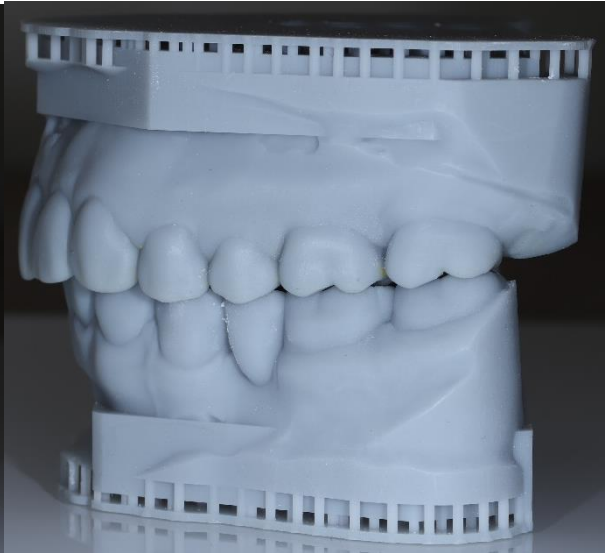
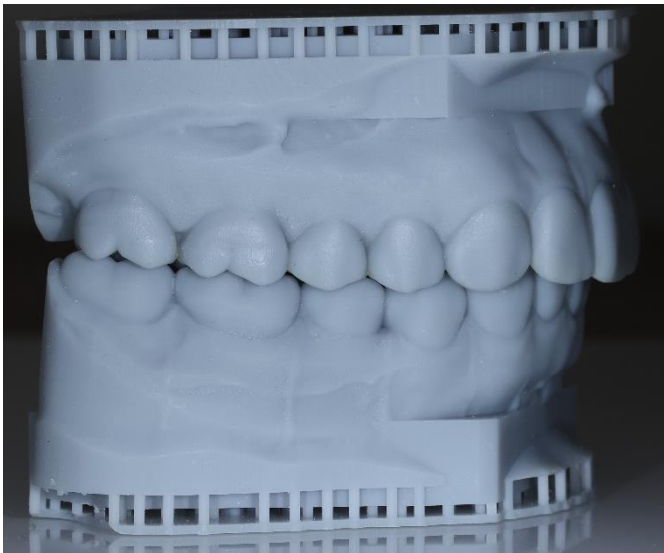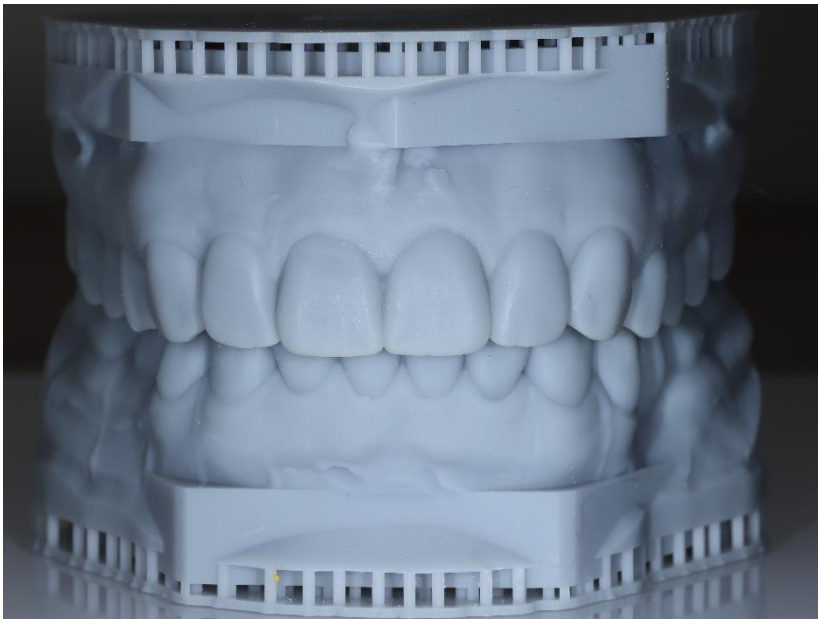**Teeth preparation**

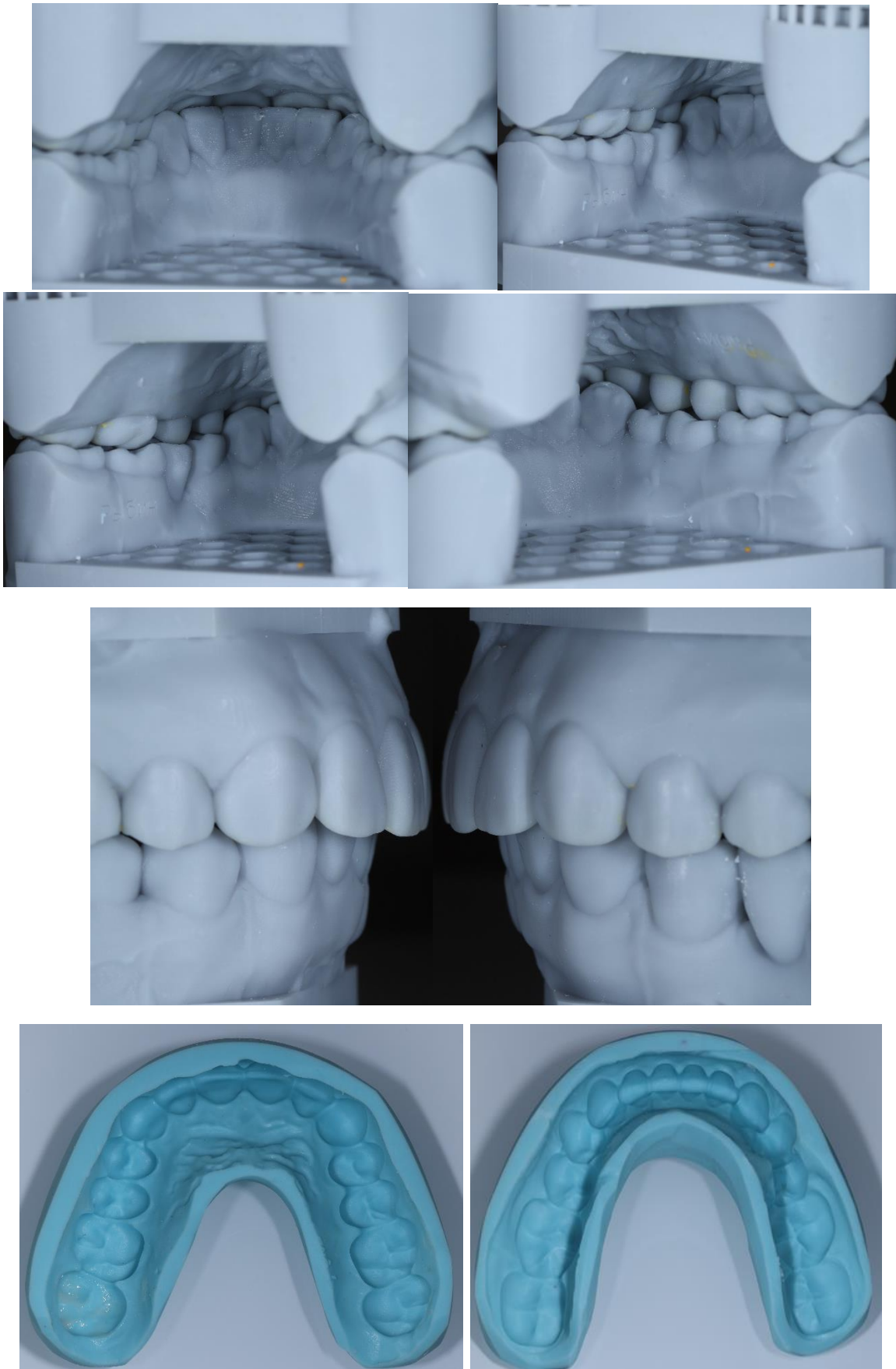


**Photos of models and silicone keys**

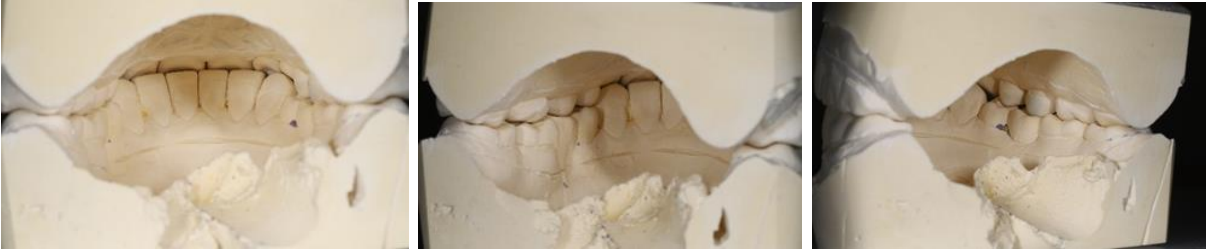
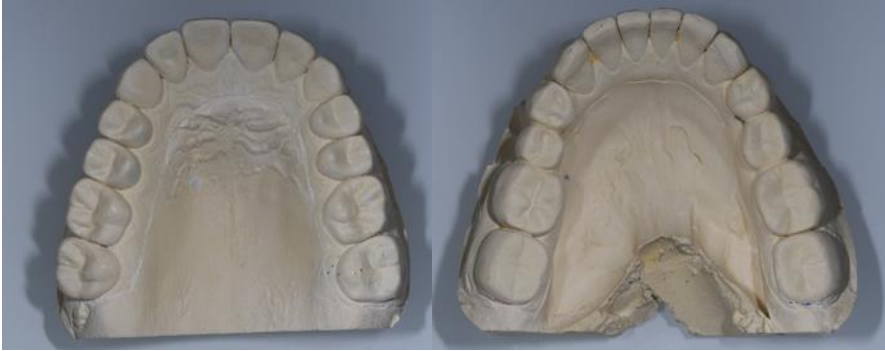
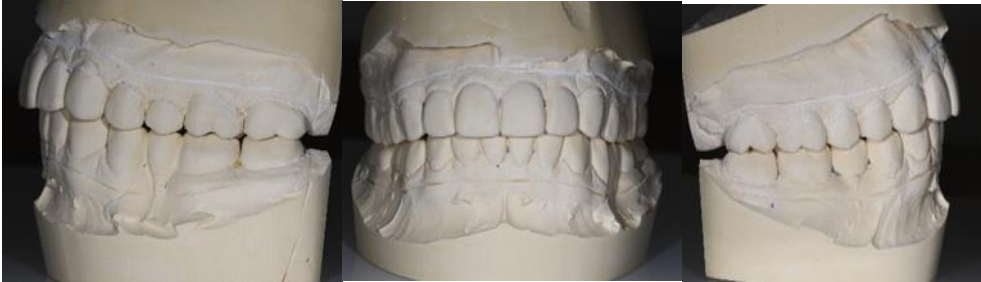




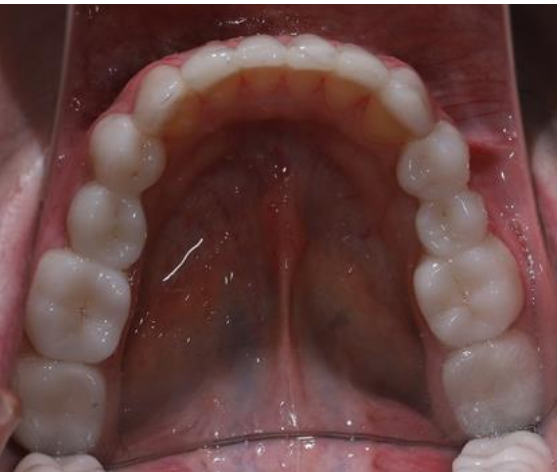
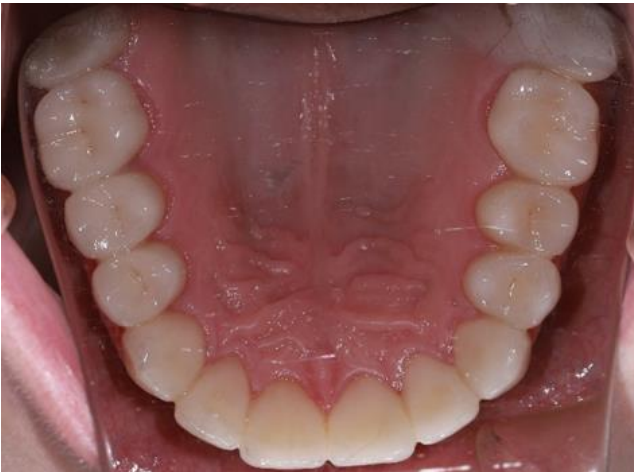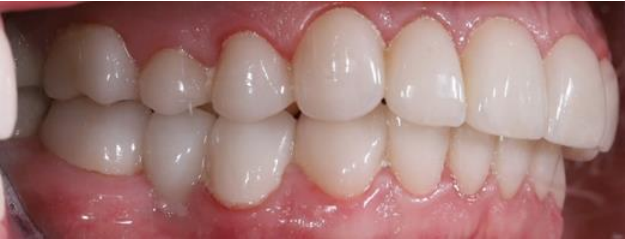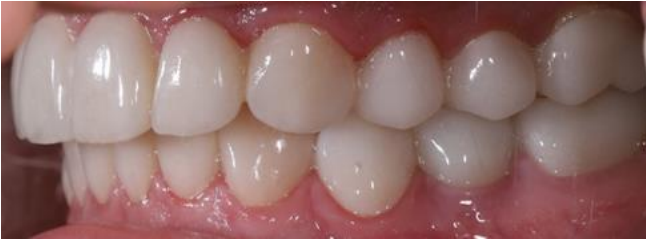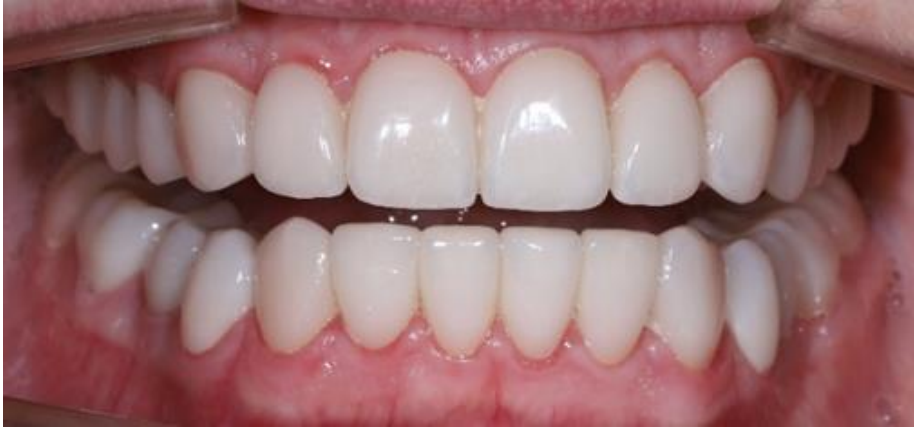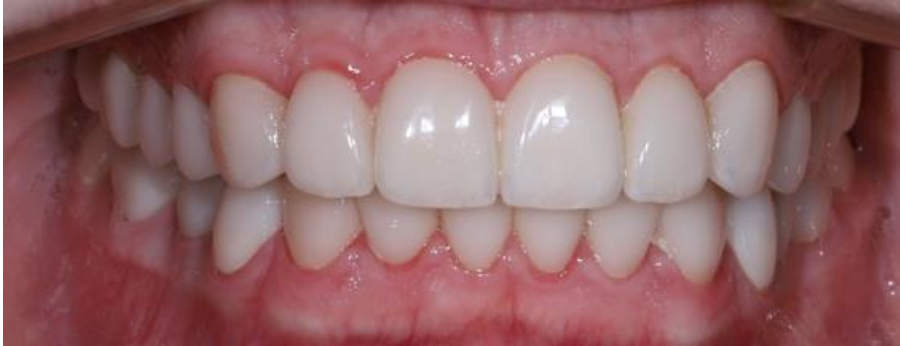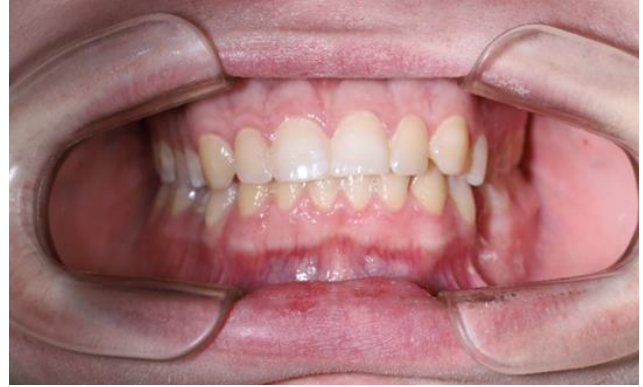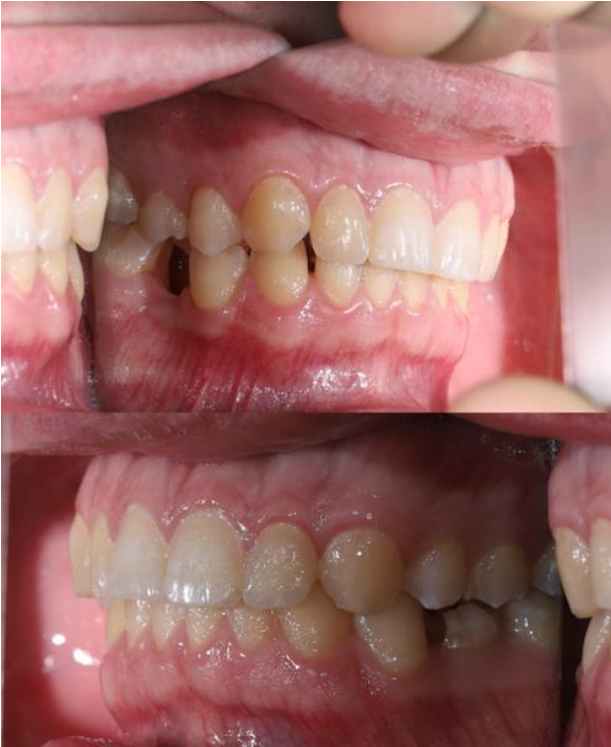ICP final restorations.



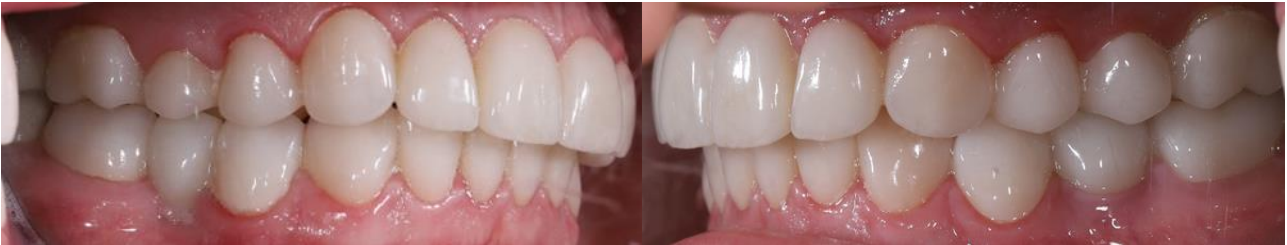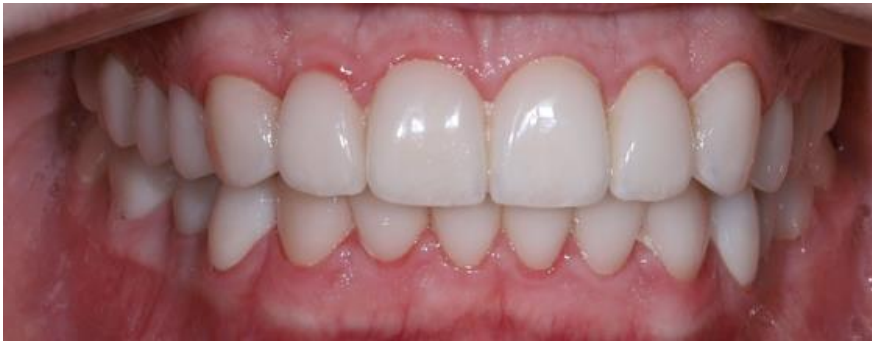**Results: Final dental restorations**



**Before January 2023**



**After March 2023**



## Clinical Case #2

Patient: female.

Date of birth 1987.

Date of examination 03.03.2023.

Chief complain – after orthodontic treatment teeth grinding, no posterior support.

**Table #1**

Special Medical Analysis			
Do you have or did ever have an illness with regard to point 1-12?			
		Yes	No
1.	Infections		X
2.	Cardo-vascular systems		X
3.	Respiratory system		X
4.	Digestive system		X
5.	Metabolic system		X
6.	Allergies		X
7.	Urogenital problems		X
8.	Central nervous system		X
9.	Psychological problems (therapy)		X
10.	Rheumatic disease		X
11.	Hormonal disease		X
12.	Special problems		X
Main concern: esthetic, low chewing efficacy			

Dental History Analysis		Valuation	Yes	No
1.	Do you have problems when you chew?			X
2.	Do you have problems when you are talking?			X
3.	Do you have problems in closing your teeth property?			X
4.	Are any of your teeth especially sensitive?	1	X	
5.	Do you have problem when you open your mouth very wide?			X

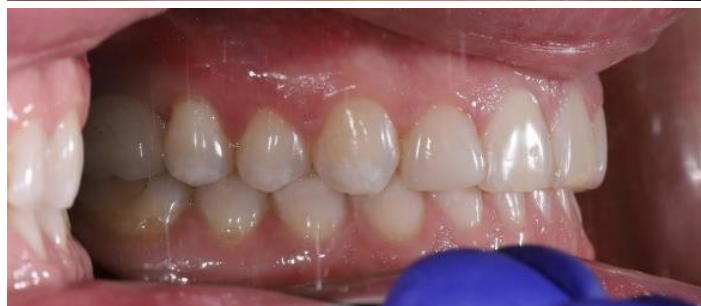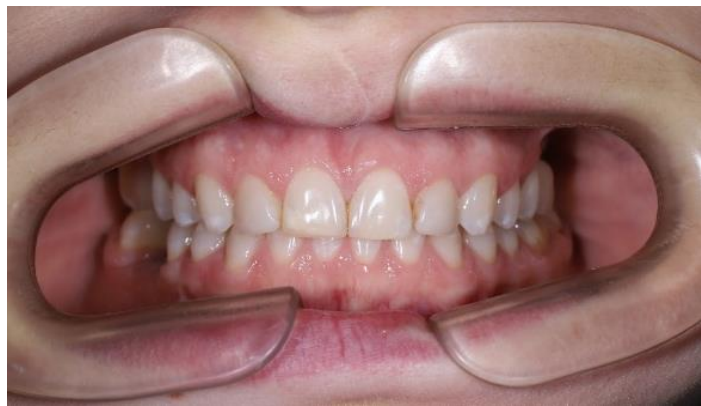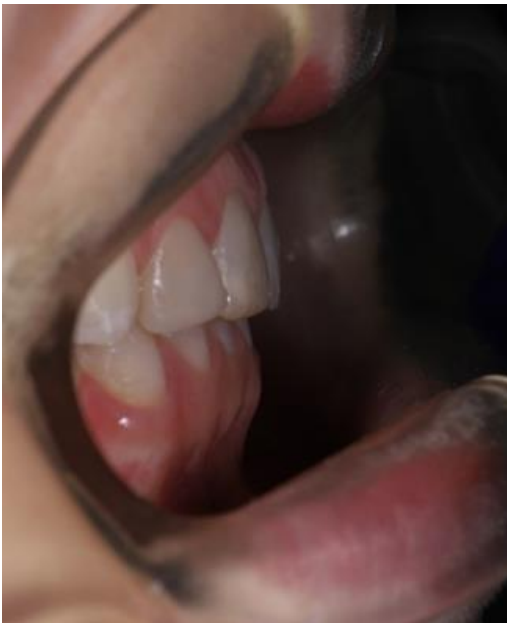6.	Do your jaw joints make noise and if so, on what side?			X		
7.	Do you have pain in the area of your jaw joints?			X		
8.	Do you suffer from headaches?			X		
9.	Do you suffer from cramps or spasm in your head, neck or throat?			X		
10.	Do you have in general problems with your posture?			X		
	Occlusal Index	1.00				
11.	Have you ever had serious accident?			X		
12.	Did you have one or more oral intubations?			X		
13.	Have you ever had orthodontic treatment or ...			X		
14.	Have you had a treatment with splint?			X		
15.	Are you grinding or pressing with your teeth?			X		
16.	Do you think that treatment is necessary?		X			
17.	Do you think that there is a serious disorder or illness?			X		
18.	When the last time you had dental treatment and what was done?					
19.	How would you describe your psychic behavior?					
	happy	sad	calm	excited	self-controlled	lack of self-control
	X					

Table #2

Muscle Diagnosis		Right		Left	
		+	++	+	++
1.	Shoulders and neck				
2.	Atlanto-occipital region				
3.a	M.temporalis ant.				
3.b	M.temporalis med.				
3.c	M.temporalis post.				
4.a	M.masseter (superficial)				
4.b	M.masseter (deep)				
5.	Tuber maxillae				
6.	M.pterygoideus medialis				
7.	M.mylohydeus				
8.	M.digastricus				

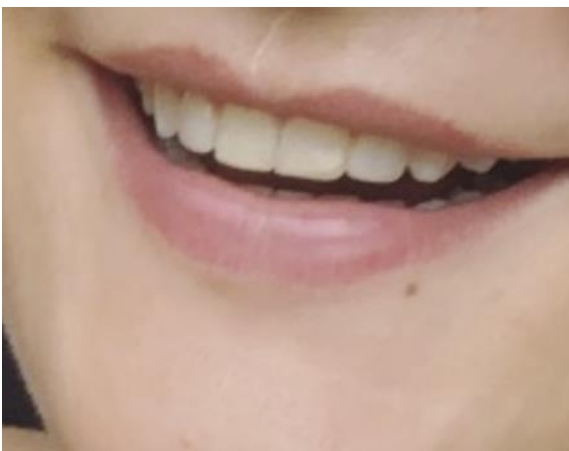
9.	Suprahyoidale M.				
10.	Infrahyoidale M.				
11.	Larynx				
12.	M.sterno-cleido-mastoideus				
13.	M.omohyoideus				
14.	Tongue				
15.	Comparative palpation of jaw joints				
	a) Lateral poles, statically				
	b) Lateral poles, in rotation	X			
	c) Retral joint space	X			
	d) Lig.temporo-mandibulare	X			

### Skeletal class I



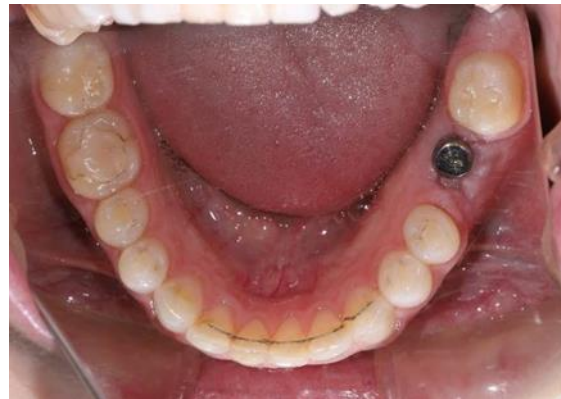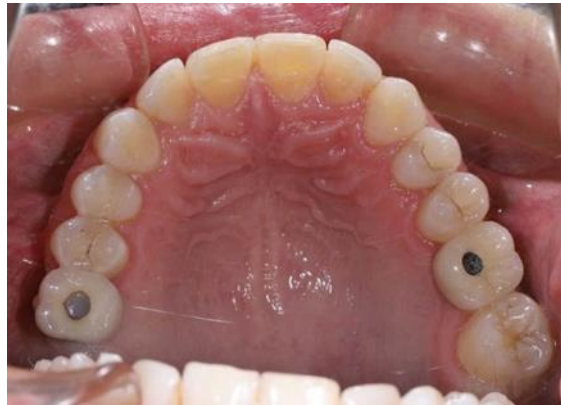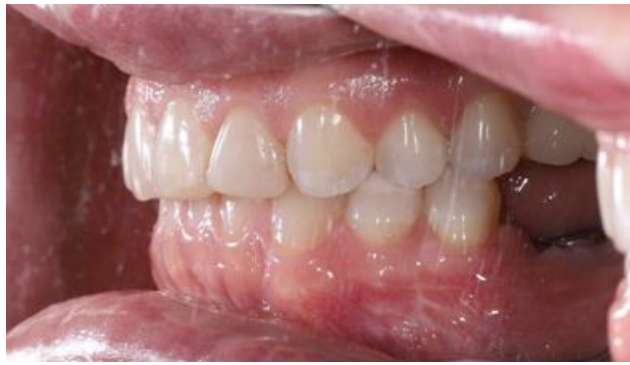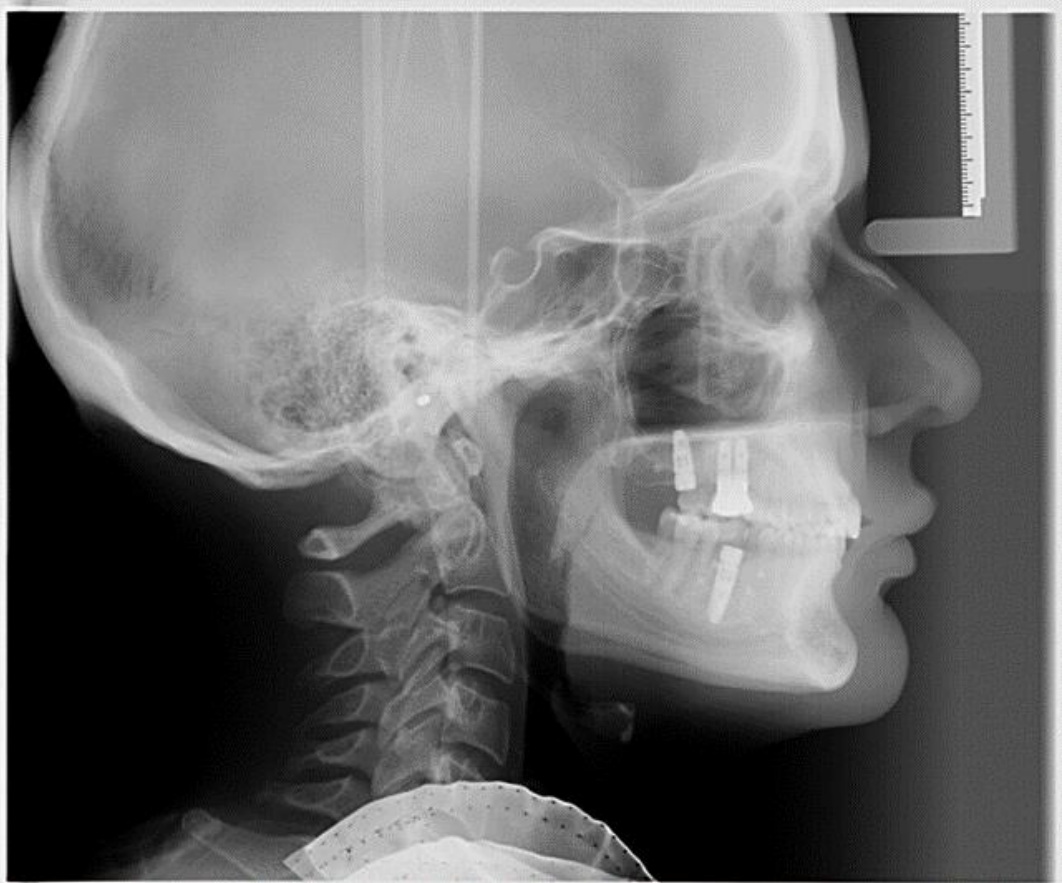


Photo 2016 after orthodontic treatment.





## Lateral X ray after comdylography

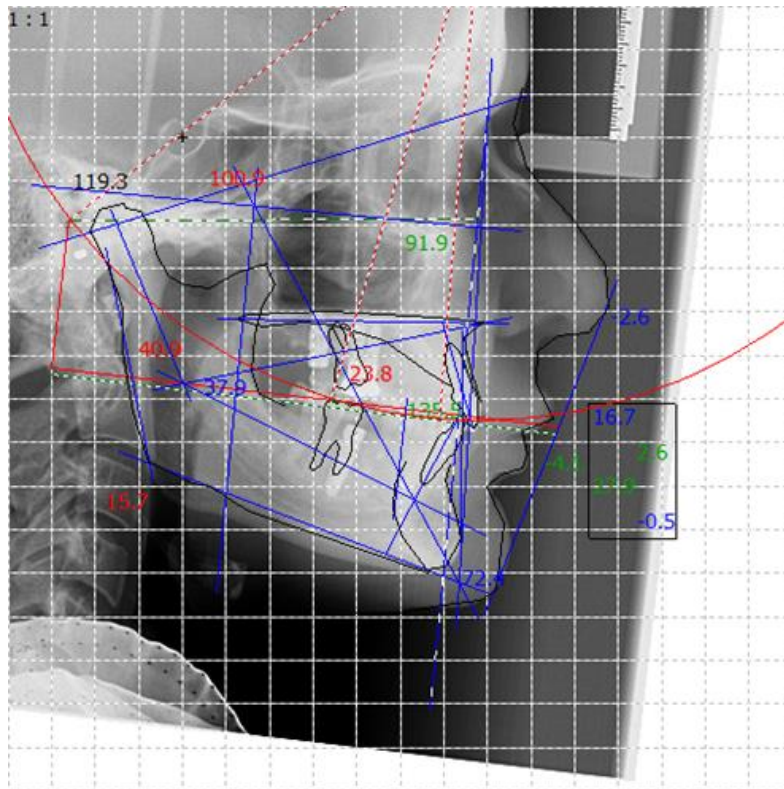


Special Medical Analysis and dental analyses

# Cephalometric analyses

Table #3

<b>Slavicek Analysis</b>			
Skeletal Measurement	Norm	Value	Trend
Facial Axis	90.0°	108.8	3B****
Facial Depth	89.0°	91.8	
Mandibular Plane	24.0°	15.6	2B**
Facial Taper	68.0°	72.4	1B*
Mandibular Arc	29.0°	40.8	2B**
Maxillary Position	65.0°	61.0	1-*
Convexity	0.0 mm	-2.6	1V*
Lower Facial Height (by R. Slavicek)	46.3°	37.8	1-*
Lower Facial Height to Point D	52.8°	42.2	1-*
Dental Measurement	Norm	Value	Trend
Interincisal Angle	131.3°	134.4	
Upper Incisor Protrusion	5.6 mm	2.5	
Upper Incisor Inclination	26.4°	16.6	1-*
Upper Incisor Vertical	Mm	2.4	
Lower Incisor Protrusion	0.9 mm	-0.4	1-*
Lower Incisor Inclination	22.3°	27.8	
Upper Molar Position	18.0 mm	23.8	2+**
Occlusal Plane	Norm	Value	Trend
Occlusal Plane – Axis Orbital Plane (Slavicek)	----°	6.6	
Idealized Occlusal Plane – Axis Orbital Plane	----°	7.8	
Distance Occlusal Plane – Axis (DPO)	40.9 mm	34.2	
Radius of Curve of Spee	mm	119.3	
Lip Embrasure	0.0 mm	1.8	
Occlusal Plane Xi Distance	-1.4 mm	0.41	
Functional Measurement	Norm	Value	Trend
Horizontal Condylar Inclination right	----°		
Horizontal Condylar Inclination left	----°		
Horizontal Condylar Inclination	----°		
Relative Condylar Inclination	----°		
Relative Condylar Inclination 6	----°		
Relative Condylar Inclination 7	----°		
Relative Condylar Inclination 8	----°		
Anterior Guidance (S-AOP)	°		
Relative Anterior Guidance	°		
Esthetic Measurement (Lip Relation)	Norm	Value	Trend
Esthetic Plane	-2.3 mm	-4.1	



## Slavicek Interactive Verbal Analysis

### Explanation

**The skeletal trend of the skull is strongly brachyfacial.**

The skeletal trend of the mandible is strongly brachyfacial.

The Skeletal class is III with tends to I.

The maxilla is positioned neutral with tendency to retrognathic.

The mandible is positioned neutral.

The lower facial height is diminished.

Dental class unknown.

The protrusion of the upper incisor is normal.

The inclination of the upper incisor is diminished.

The protrusion of the lower incisor is diminished.

The inclination of the lower incisor is normal.

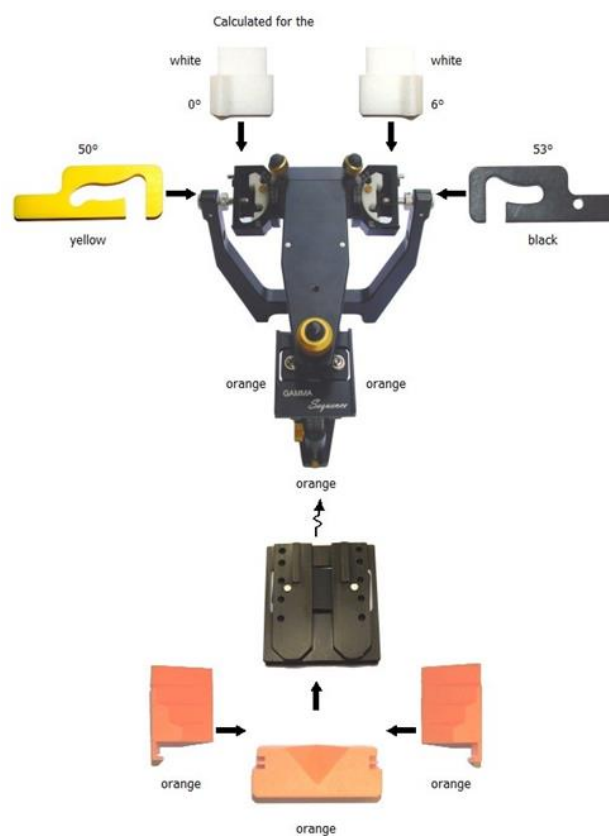
The interincisal angle is normal.

Occlusal concept: Tendency to group function.

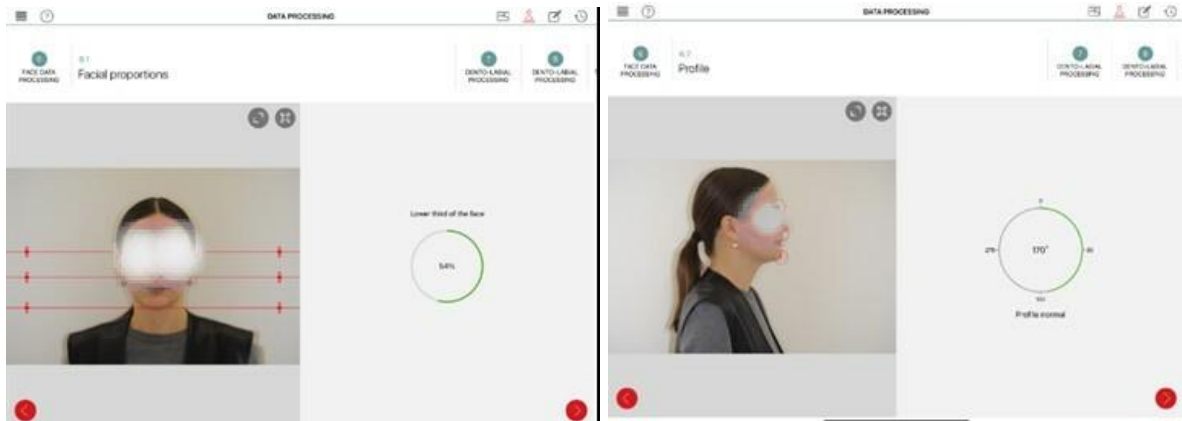
**Table 4**

Determinants	Norm	Value	Trend
Facial Axis	90.0°	100.8	3B***
Facial Depth	89.0°	91.8	
Facial Taper	68.0°	72.4	1B*
Mandibular Plane	24.0°	15.6	2B*
Related Values	Norm	Value	Trend
Bjoerk Sum	396.0°	386.1	3-***
Facial Length Ratio	63.5%	69.2	2+**
Y Axis to S N	67.0°	63.9	1-*
Y Axis (Downs)	61.2°	52.6	2-**
S N to Gonion Gnathion Angle	32.6°	26.1	1-*

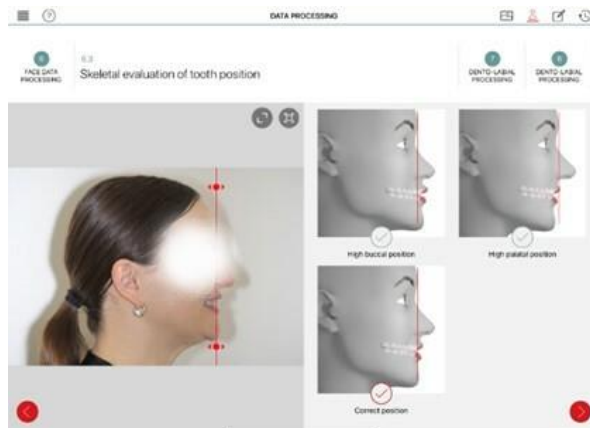
### Articulator settings



# Esthetic analyses



## Face Profile



### VIDEOS OF PATIENT

Right lateral view of "F" Sound



Left lateral view of "F" Sound



Natural smile



"S" Sound

Natural rest position

### COLOR SELECTION

---

SHADE GUIDE


DESIRED COLOR OF THE RESTORATION: 01

Value: High 


 Low

ABUTMENT COLOR



### DIMENSIONAL CHANGES

---









ORIGINAL LENGTH OF THE REFERENCE CENTRAL INCISOR	8mm
change length	-2,5mm
ORIGINAL WIDTH OF THE REFERENCE CENTRAL INCISOR	8mm
change width	0mm


ORIGINAL LENGTH OF THE REFERENCE CENTRAL INCISOR	6,8mm
change length	-0,6mm
ORIGINAL WIDTH OF THE REFERENCE CENTRAL INCISOR	8mm
change width	0mm

### ESTHETIC INFORMATION

---

HIGHLY DEMANDING PATIENT	Yes
ALIGNMENT	Yes
APPEARANCE	Adult
TOOTH TYPE	Ovoid
MACRO TEXTURE	Slight
COLOR CHARACTERIZATION	Wide and uniform
SMILE LINE	Average
The visibility of the anterior teeth suggest y	
LABIAL CORRIDOR	Wide
Increase the buccal volume of the posterio	
SMILE WIDTH	12-14
Take care of the esthetics of the buccal an	
INTERINCISAL LINE INCLINATION	Left inclination
Straighten the interincisal line	
OCCUSAL PLANE ORIENTATION	Right inclination
Realigne the occlusal plane orientation to l	
INCISAL EDGE POSITION	Ideal
Missing information.	

19:43 19/11/2023 DATA COLLECTION

1.8 Treatment requested by the patient

Alignment

Yes  No

Appearance

Young  Adult  Mature

Tooth type

Triangular  Ovoid  Square

Macro texture

No  Slight  Pronounced

Color characterization

White and uniform  Slightly characterized  Highly characterized

Highly demanding patient?  Yes  No

19:44 19/11/2023 DATA COLLECTION

1.6 Subjective perception

1.7 Treatment requested by the patient

Aesthetic

Color  Black triangles  Failed restoration  Dental crowding  Diastema  Gingival anomalies  Tooth wear  Long/short teeth  Upper anteriors  Lower anteriors  Full upper arch  Full lower arch  Diastema closure  Teeth re-alignment

Function

Tooth fracture  Tooth mobility  Masticatory dysfunction  Facial pain

Notes

\_\_\_\_\_

\_\_\_\_\_

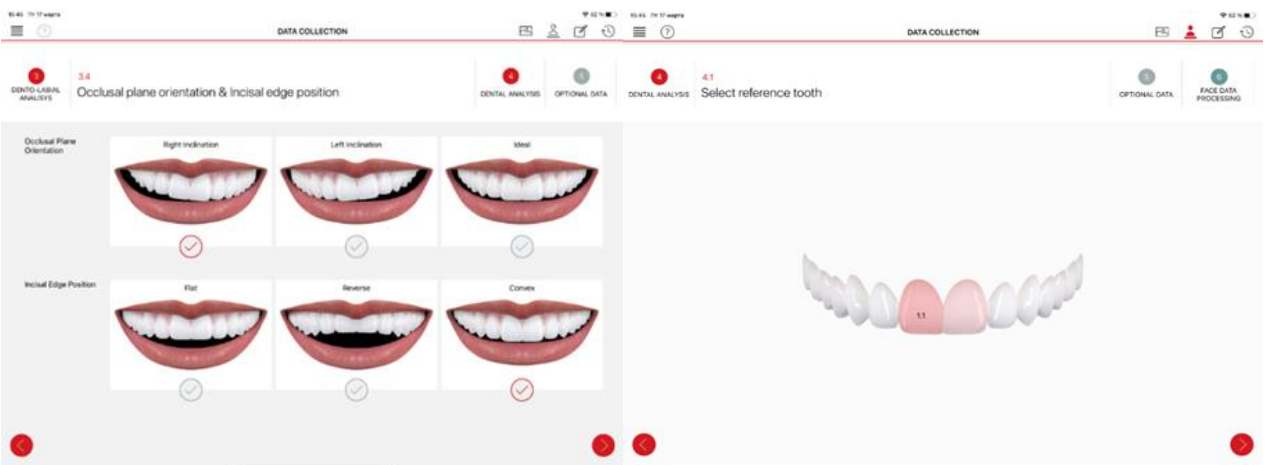
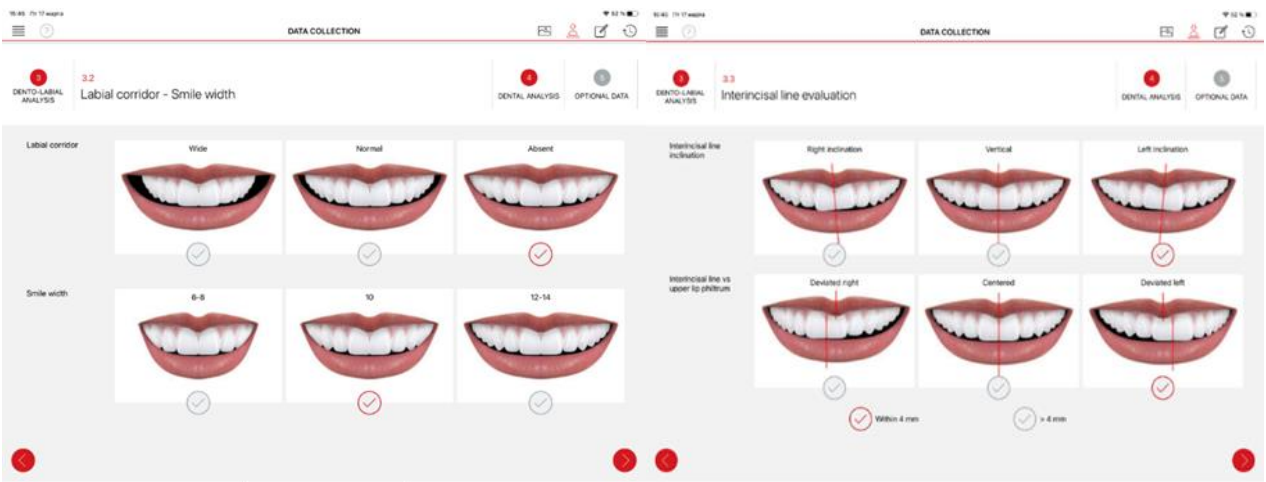
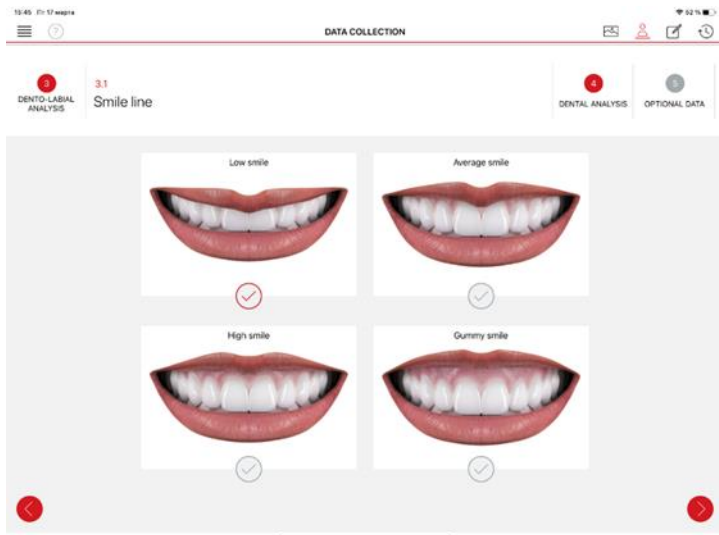
\_\_\_\_\_

\_\_\_\_\_

19:45 19/11/2023 DATA COLLECTION

2.3 Videos of the patient

Right lateral view of "F" sound  Left lateral view of "F" sound  Natural smile  "F" sound  Natural rest position





15:45 17 weeks DATA COLLECTION DATA COLLECTION

4.2 Upper central incisor dimension

4.3 Lower central incisor dimension

OPTIONAL DATA FACE DATA PROCESSING DENTAL ANALYSIS

Proportion

tooth: 1.1

length: 8.0 mm

width: 8.0 mm

exposure at rest: 5.0 mm

Upper incisor exposure at rest (reference tooth): this data can be collected by measuring the distance between the incisal margin of the tooth and the upper lip. This value can be either positive if the tooth is visible or negative if the tooth is not visible. [View Example](#)

Proportion

tooth: 0.7

length: 8.5 mm

width: 8.0 mm

exposure at rest: 0.0 mm

Lower incisor exposure at rest (reference tooth): this data can be collected by measuring the distance between the incisal margin of the tooth and the lower lip. This value can be either positive if the tooth is visible or negative if the tooth is not visible. [View Example](#)

15:45 17 weeks DATA COLLECTION DATA COLLECTION

4.4 Anterior occlusal relationship

OPTIONAL DATA FACE DATA PROCESSING

overbite: 4.0 mm

overjet: 4.5 mm

Anterior Dental Contact:  Yes  No

interocclusal distance: 4.2 mm

Incisal Wear:  Yes  No

Palatal Wear:  Yes  No

15:45 17 weeks DATA COLLECTION DATA COLLECTION

4.7 Evaluation of the lower incisors

OPTIONAL DATA FACE DATA PROCESSING

Does the lower incisal plane match the posterior occlusal plane?

Under erupted:  Yes:  Over erupted:

Value (mm): -5.0 -4.5 -4.0 -3.5 -3.0 -2.5 -2.0 -1.5 -1.0 -0.5 0 +0.5 +1.0 +1.5 +2.0 +2.5 +3.0 +3.5 +4.0 +4.5 +5.0

16:44 7/17 steps DATA PROCESSING

6.3 Skeletal evaluation of tooth position

7.1 Reference lines

Interorbital line

Reference for the rehabilitation

Bipupillar

Horizon

90°

0°

-120°

-90°

zoom size

MT pupill

right pupill

clear

16:46 7/17 steps DATA PROCESSING

6.1 Facial proportions

6.2 Profile

Lower third of the face

54%

170°

Profile normal

16:48 7/17 steps DATA PROCESSING

7.2 Zoom and crop the upper and lower arch

7.3 Definition of the central incisor length

tooth	1.1
length	9.0 mm
width	6.0 mm
exposure at rest	5.0 mm

Ratio %

89%

This is the ratio between the length and width of the reference incisor as per the initial conditions. In the following steps it will be possible to modify these values so to alter the ratio.

16:49 7/17 steps DATA PROCESSING

7.4 Definition of the central incisor width

7.5 Definition of the central incisor length

tooth	1.1
length	9.0 mm
width	6.0 mm
exposure at rest	5.0 mm

Ratio %

89%

In the following step the tooth length will be modified to reach ideal tooth proportions and optimize the value of tooth exposure at rest.

tooth	1.1
length	9.4 mm
width	6.0 mm
final tooth exposure at rest	5.4 mm
buccal lengthening	0.4 mm
marginal cervical shift	0.0 mm

Ratio %

89%

The arch has been optimized according to the tooth dimensions.

19:47 76% DATA PROCESSING DATA PROCESSING

76 Incisal edge optimization

8.1 Incisal profile

11 11.1

length 11.8 mm

width 8.0 mm

final tooth exposure at rest 7.3 mm

incisal lengthening 2.5 mm

marginal cervical shift 0.0 mm

Ratio % 70%

Angle between Camper's plane and the central incisor axis 95°

Move palatally 1.0 mm

19:47 76% DATA PROCESSING DATA PROCESSING

8.2 Phonetics - "F" sound

Version

Lingualized

Rocculated

19:47 76% DATA PROCESSING DATA PROCESSING

9.2 Prosthetic solutions

10.1 Definition of the upper teeth size

11 length/horizon 1.0 mm

12 length/horizon 0.0 mm

13 length/horizon 1.0 mm

21 length/horizon 0.0 mm

22 length/horizon 0.0 mm

23 length/horizon 0.5 mm

11 width/horizon 0.0 mm

12 width/horizon 0.0 mm

13 width/horizon 0.0 mm

21 width/horizon 0.0 mm

22 width/horizon 0.0 mm

23 width/horizon 0.0 mm

19:47 76% DATA PROCESSING DATA PROCESSING

10.1 Definition of the upper teeth size

10.3 Buccal-labial teeth movement

11 lingual 3.3 mm

12 buccal/labial 0.0 mm

13 buccal/labial 0.0 mm

21 buccal/labial 0.0 mm

22 buccal/labial 0.0 mm

23 buccal/labial 0.0 mm

11 length/horizon 0.8 mm

12 length/horizon 0.2 mm

13 length/horizon 0.5 mm

21 length/horizon 0.0 mm

22 length/horizon 0.0 mm

23 length/horizon -0.8 mm

11 width/horizon 0.0 mm

12 width/horizon 0.0 mm

13 width/horizon 0.0 mm

21 width/horizon 0.0 mm

22 width/horizon 0.0 mm

23 width/horizon 0.0 mm

most buccally

most labially

rotate

direct movement

clear

04:17 7/17 steps DATA PROCESSING

10.6 Definition of the lower teeth size

LAB CHART SUMMARY AND FINAL NOTES

10.7 Buccal-labial teeth movement

LAB CHART SUMMARY AND FINAL NOTES

17 length buccal	0.0 mm	18 width buccal	0.0 mm
22 length buccal	0.0 mm	23 width buccal	0.0 mm
27 length buccal	0.0 mm	28 width buccal	0.0 mm
32 length buccal	0.0 mm	33 width buccal	0.0 mm
37 length buccal	0.0 mm	38 width buccal	0.0 mm
42 length buccal	0.0 mm	43 width buccal	0.0 mm
47 length buccal	0.0 mm	48 width buccal	0.0 mm
52 length buccal	0.0 mm	53 width buccal	0.0 mm
57 length buccal	0.0 mm	58 width buccal	0.0 mm

- 41 buccolingual 0.0 mm
- 42 buccolingual 0.0 mm
- 43 buccolingual 0.0 mm
- 31 buccolingual 0.0 mm
- 32 buccolingual 0.0 mm
- 33 buccolingual 0.0 mm

move locally move globally rotate movement delete clear

04:17 7/17 steps DATA PROCESSING

11.0 Laboratory work order

LAB CHART REVIEW LAB CHART

11.2 Functional aspects

LAB CHART SUMMARY AND FINAL NOTES

Diagnostic wax up  Indirect wax up  Provisional prosthesis  Final prosthesis

Notes

Diagnosis wax up and provisional prosthesis related notes

Notes

Removal  Final pattern  Center pattern  Global function

Function  Retain  Unretain  Other

04:18 7/17 steps DATA PROCESSING

11.4 Mock-up matrix selection

LAB CHART REVIEW LAB CHART

11.5 Type of restoration (upper arch)

LAB CHART SUMMARY AND FINAL NOTES REVIEW

Transparent matrix  Matrix for preparation thickness checking - frontal view  Matrix for preparation thickness checking - occlusal view

Stone matrix

Matrix for preparation thickness checking - lateral view

Notes

Notes

Occlusal coverage Buccal coverage Full coverage

04:18 7/17 steps DATA PROCESSING

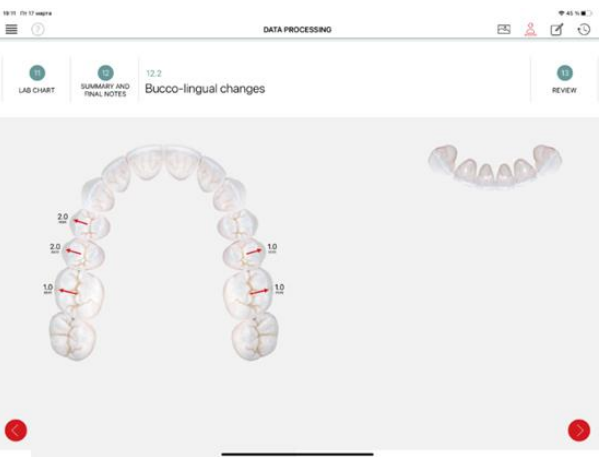
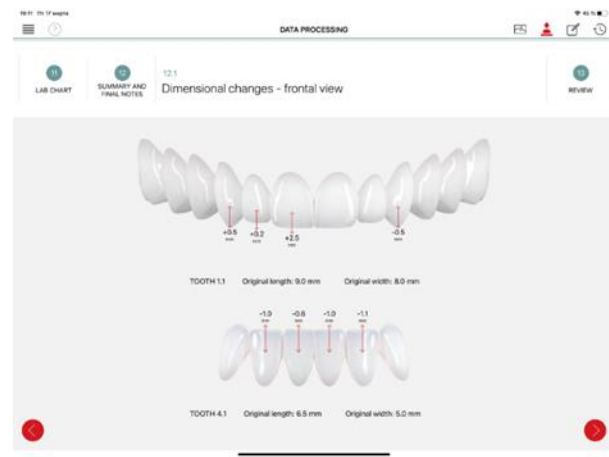
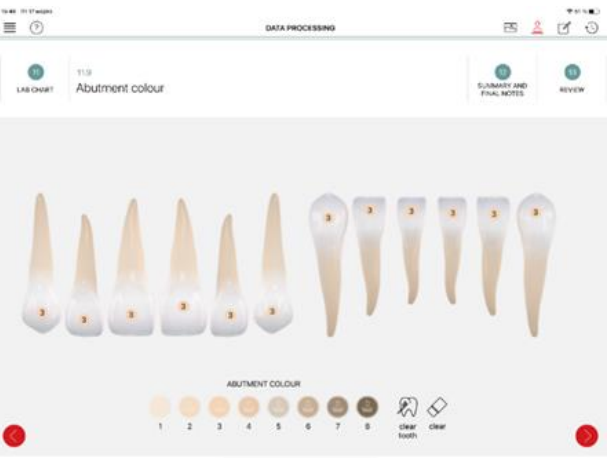
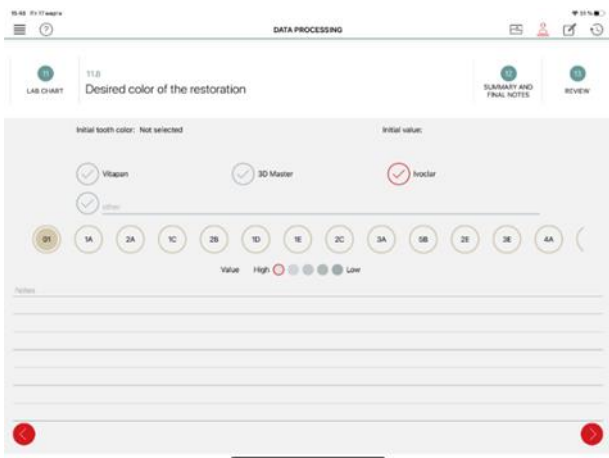
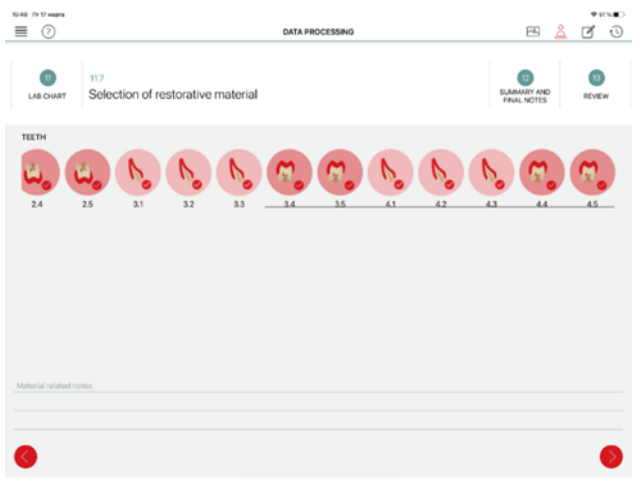
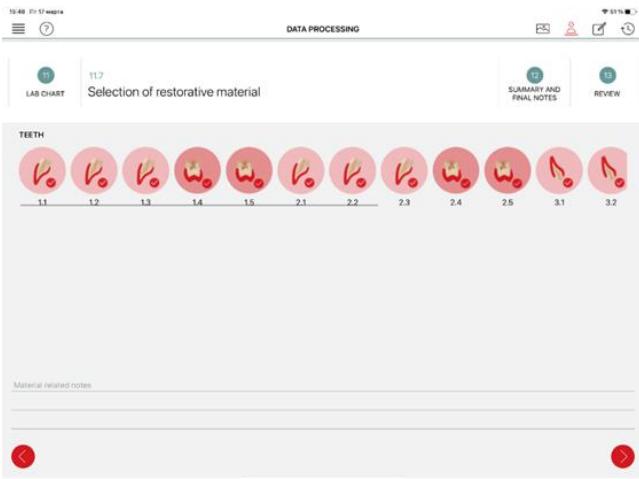
11.6 Type of restoration (lower arch)

PROSTHETIC SOLUTION LAB CHART SUMMARY AND FINAL NOTES

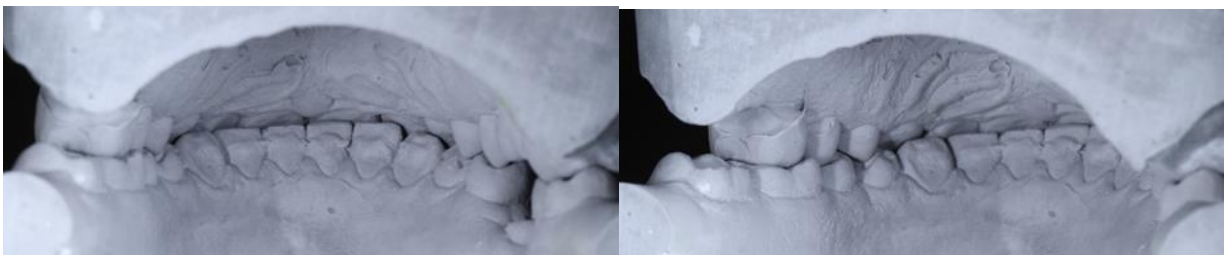
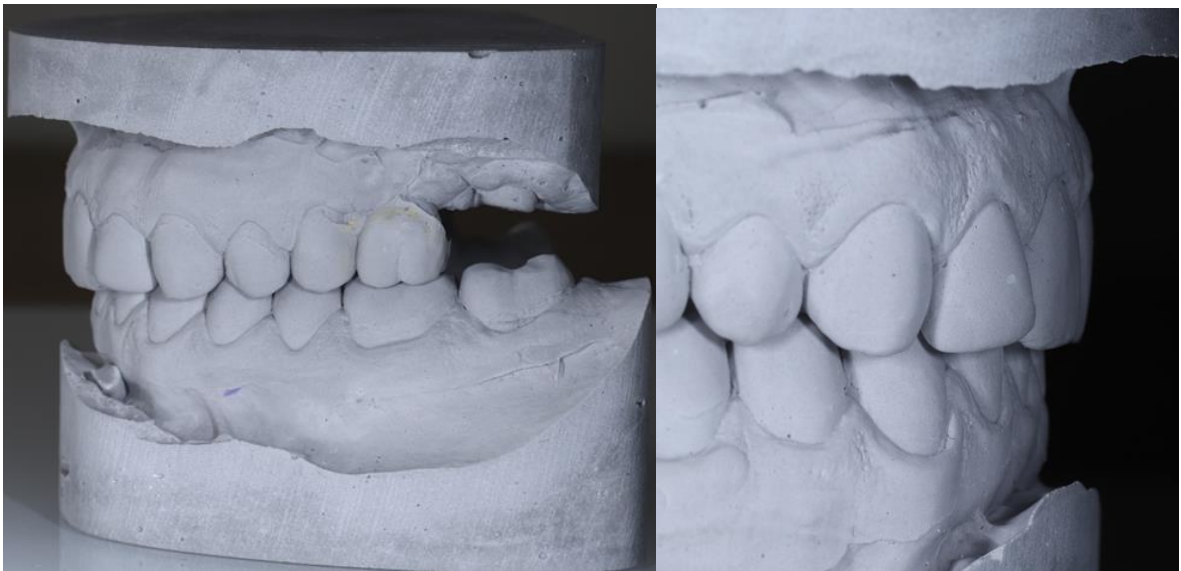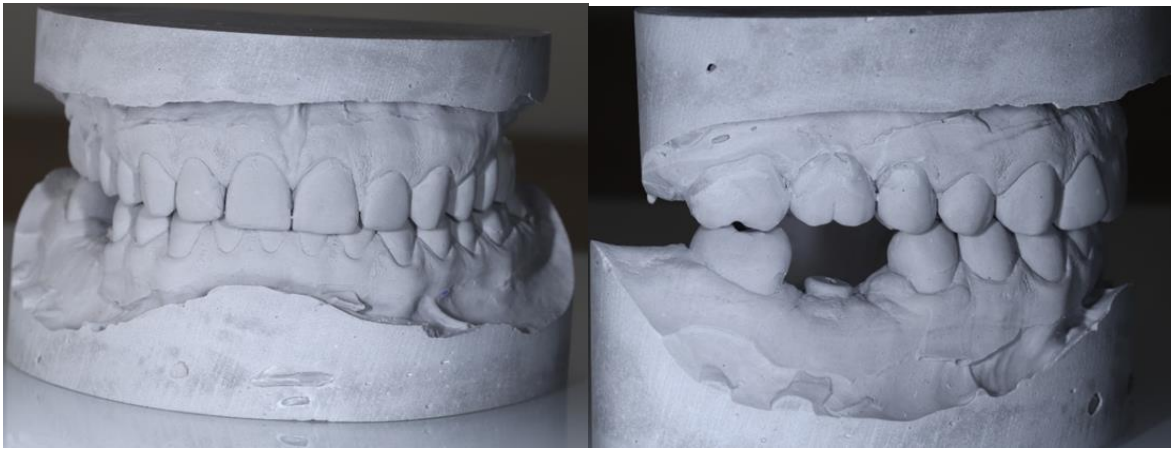
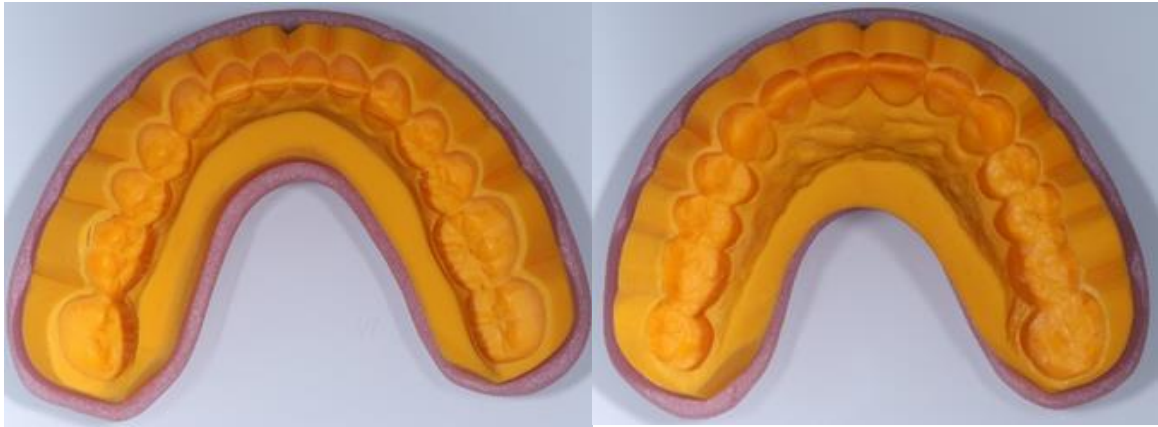LAB CHART REVIEW

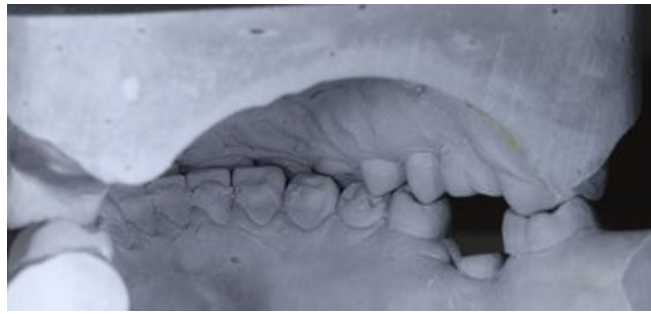
clear tooth clear

Occlusal coverage Buccal coverage Full coverage

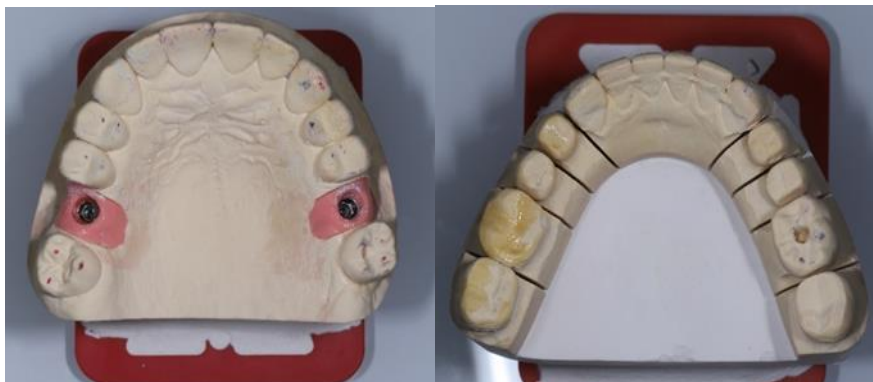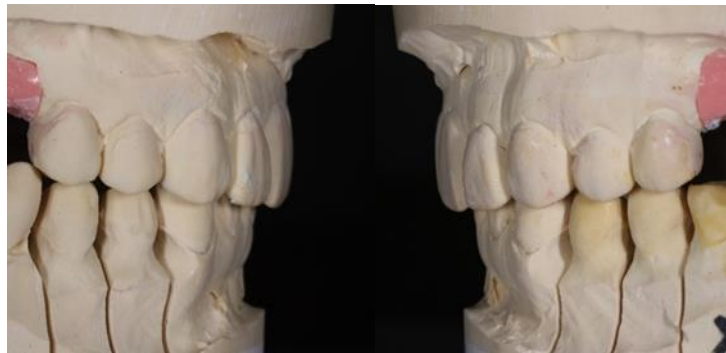
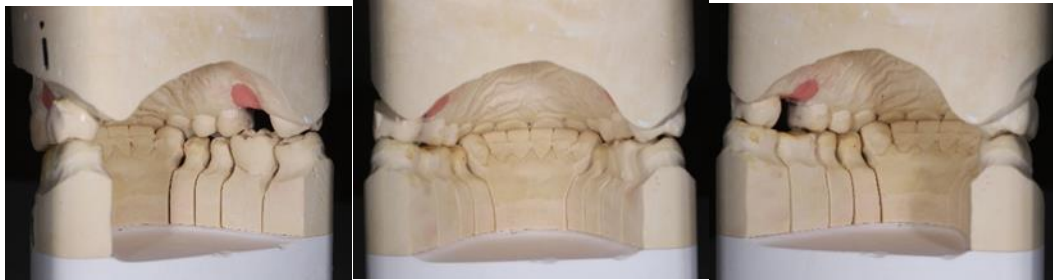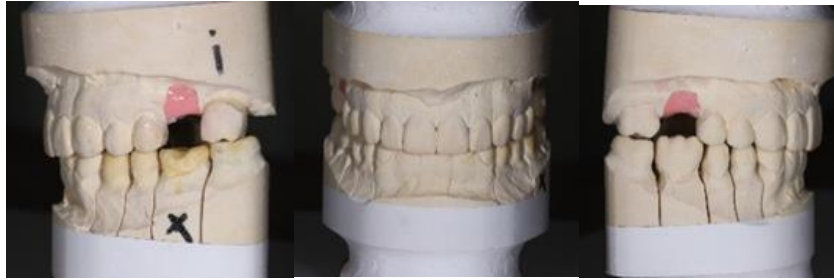


# ICP

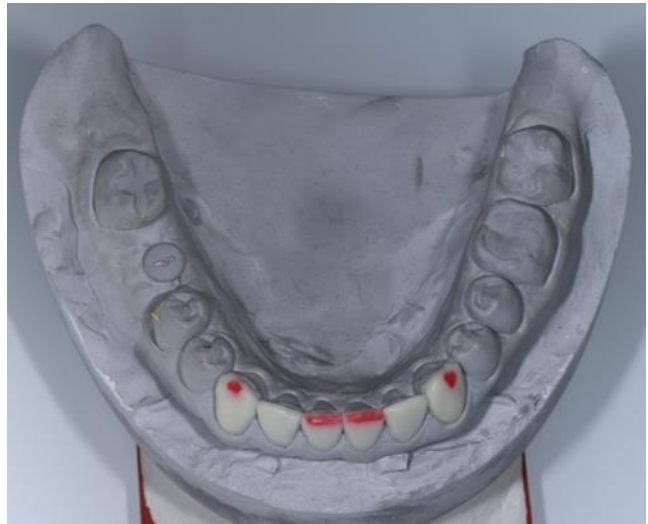
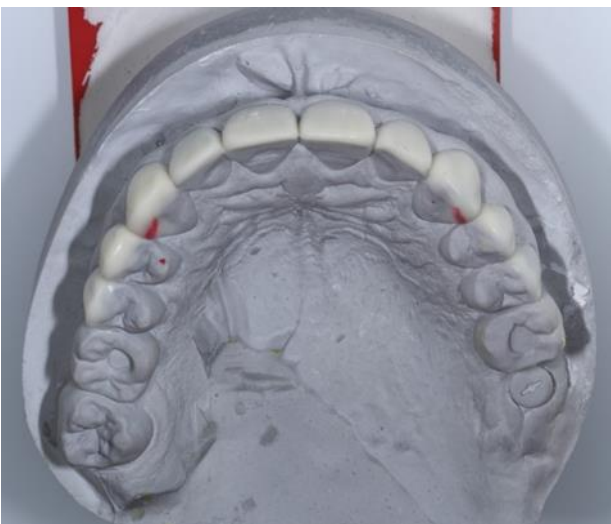
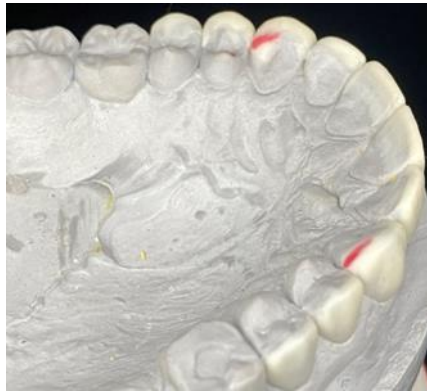
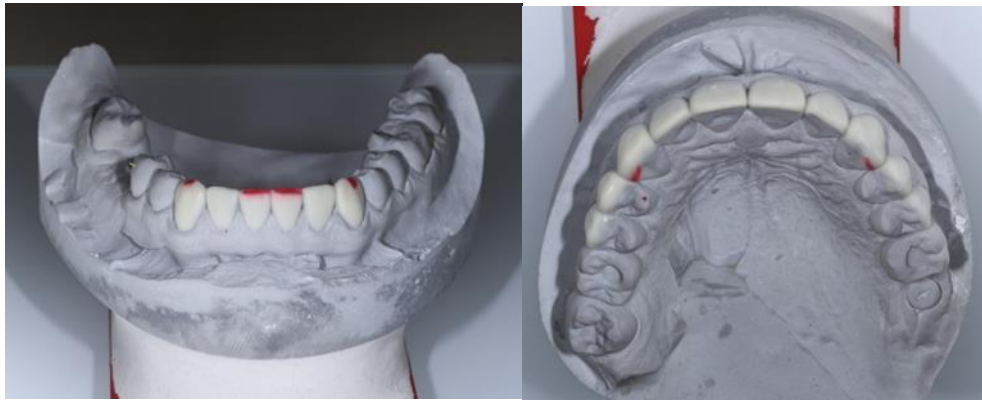
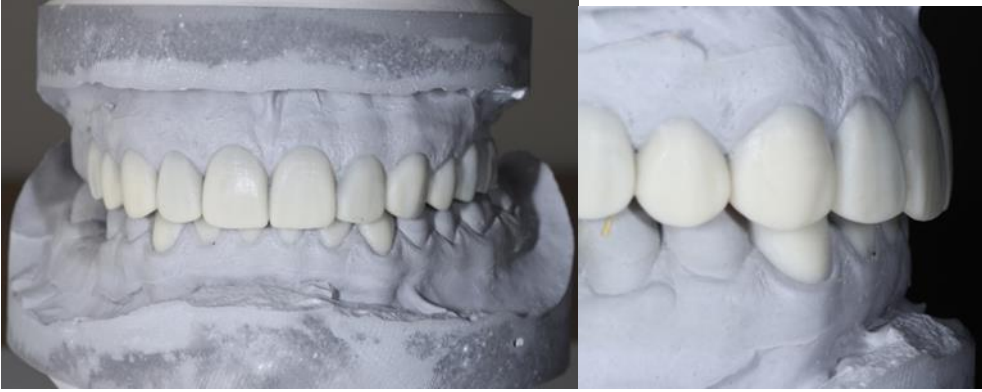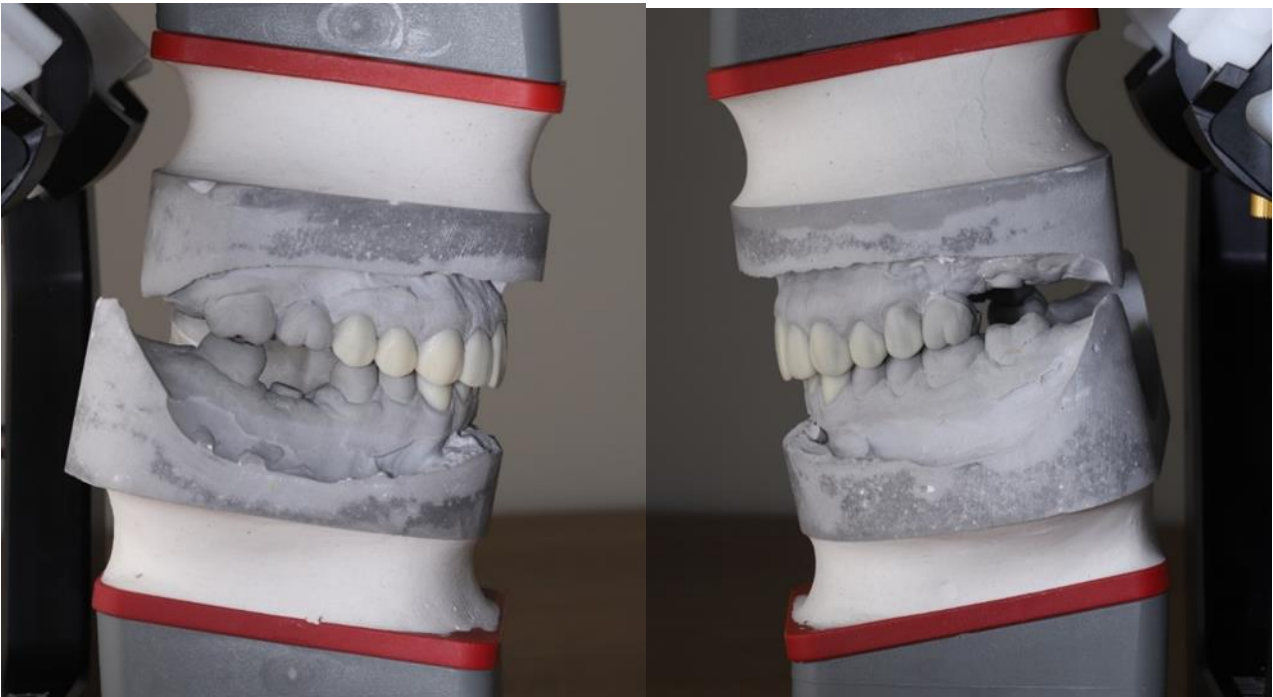
### Casts in RP



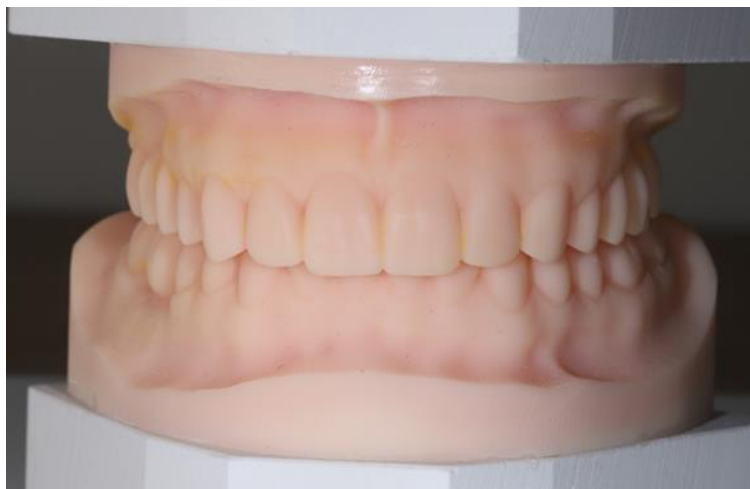## Casts with Wax-up

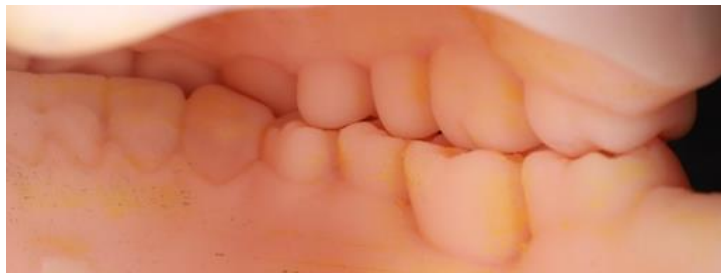
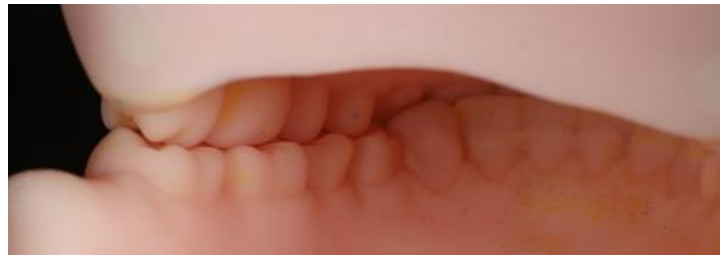
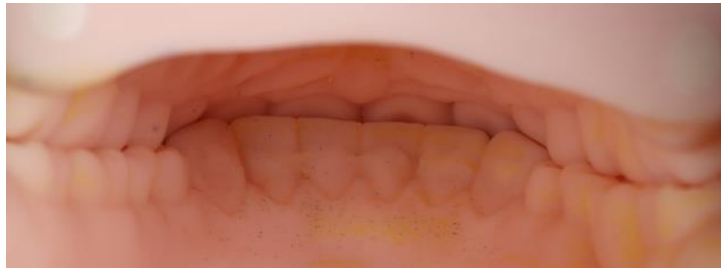
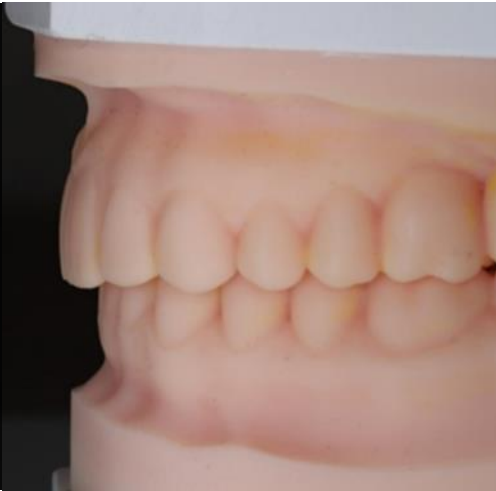
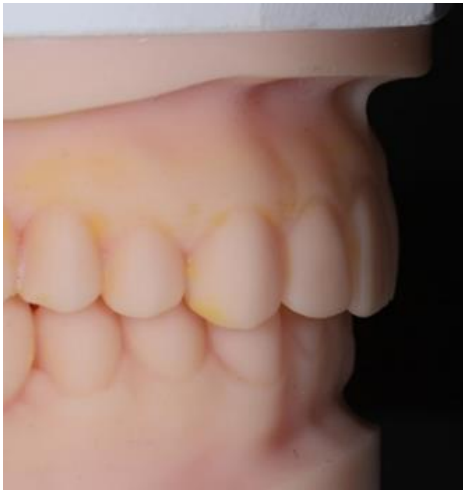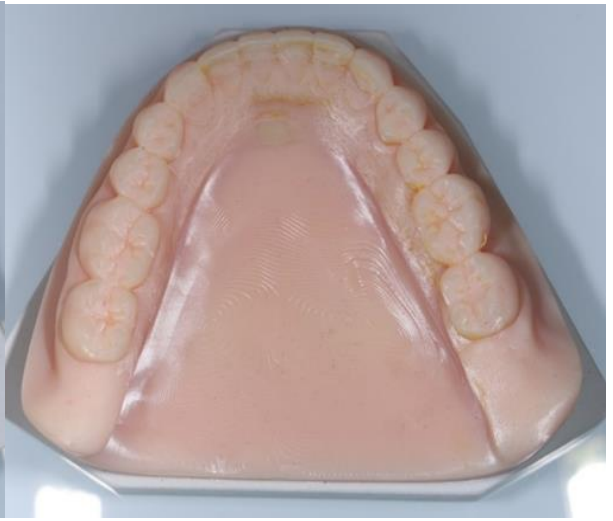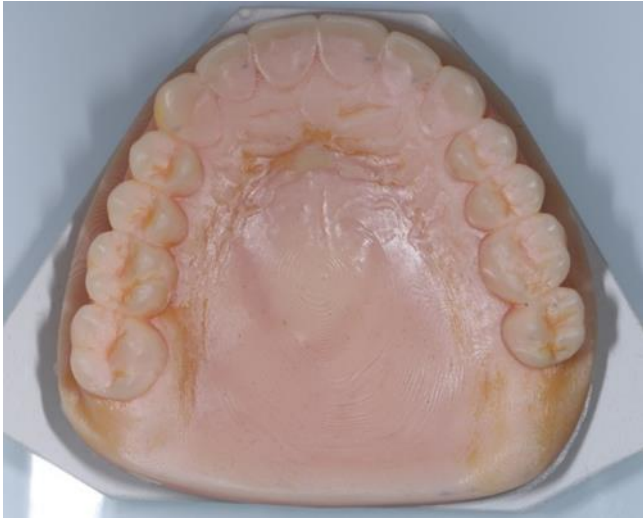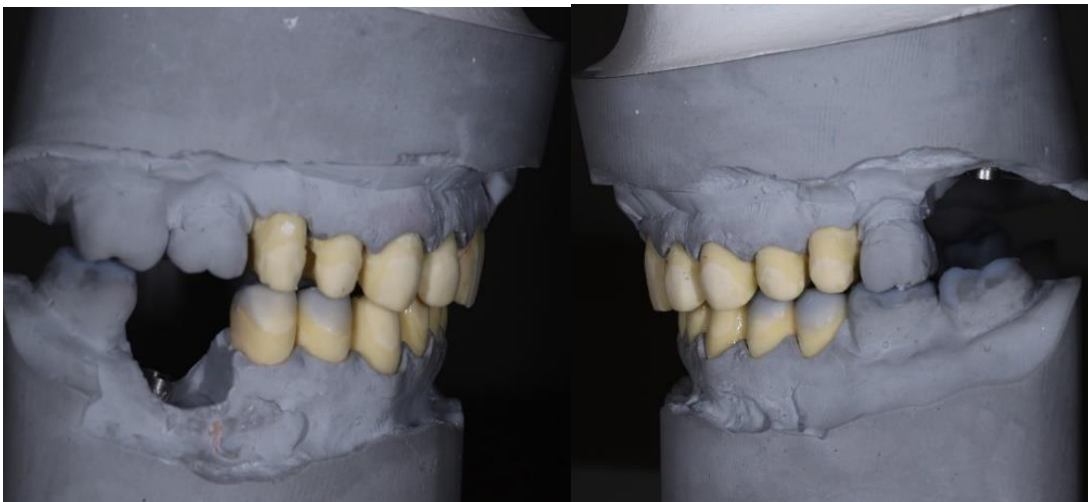
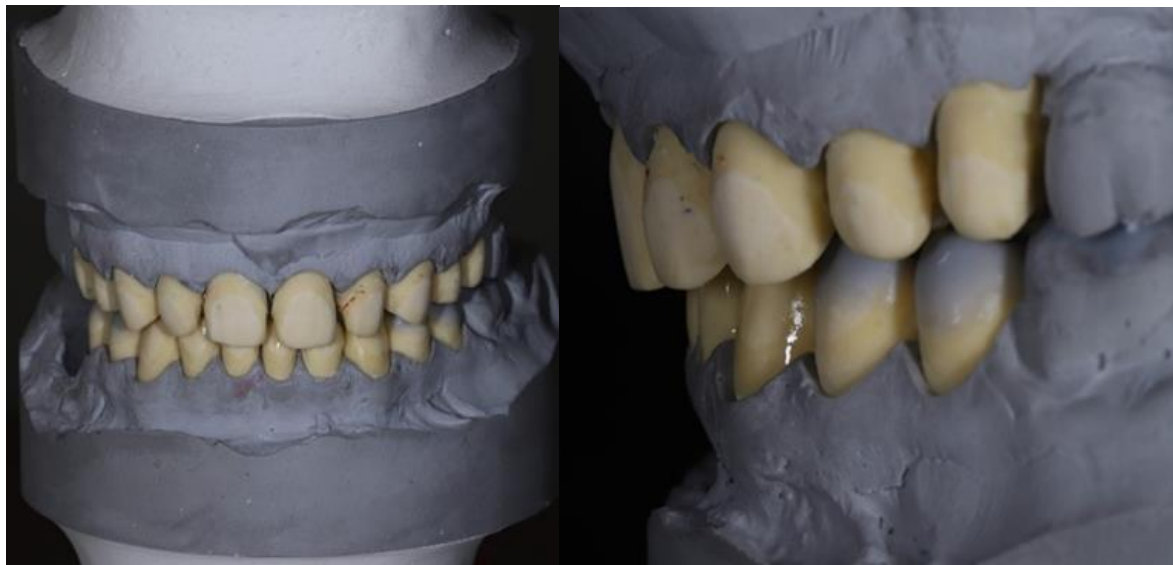


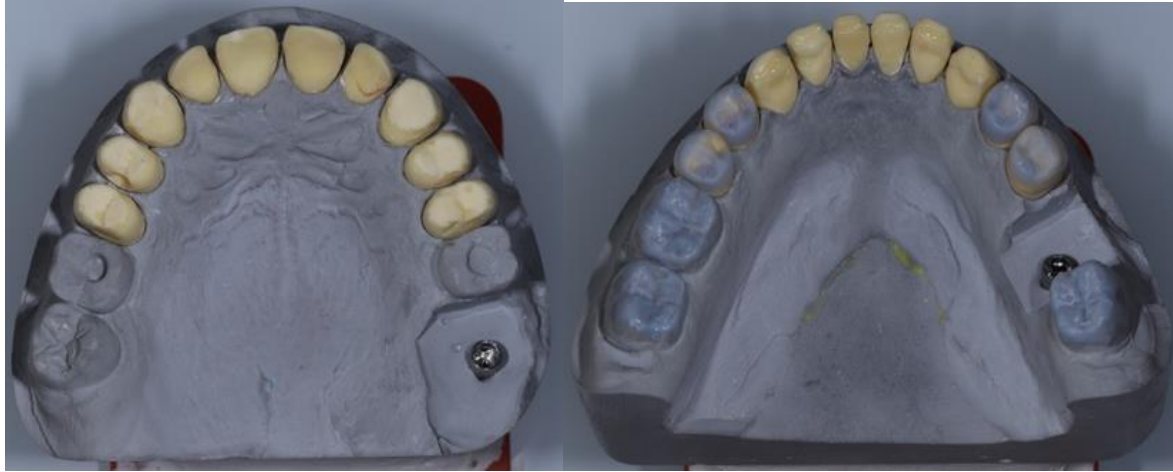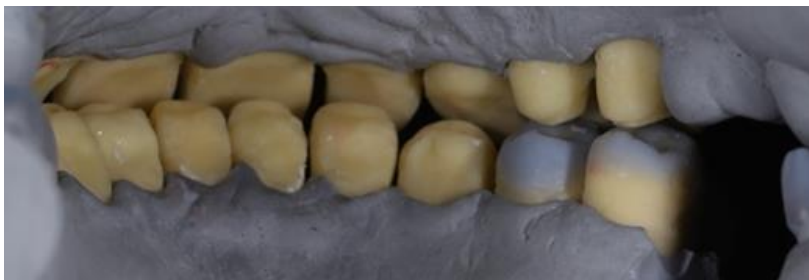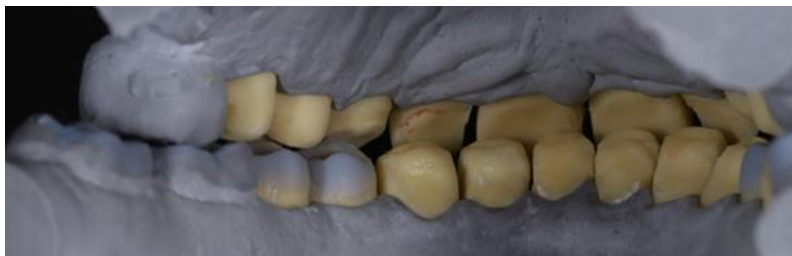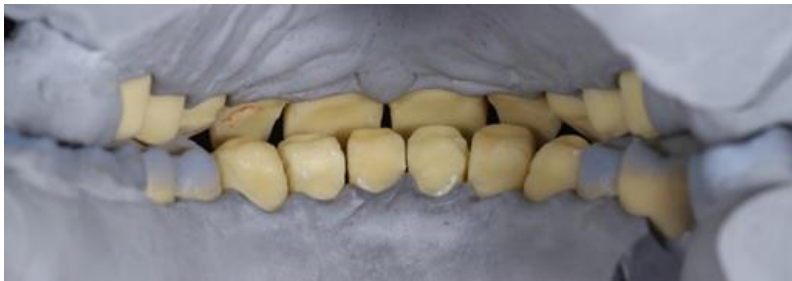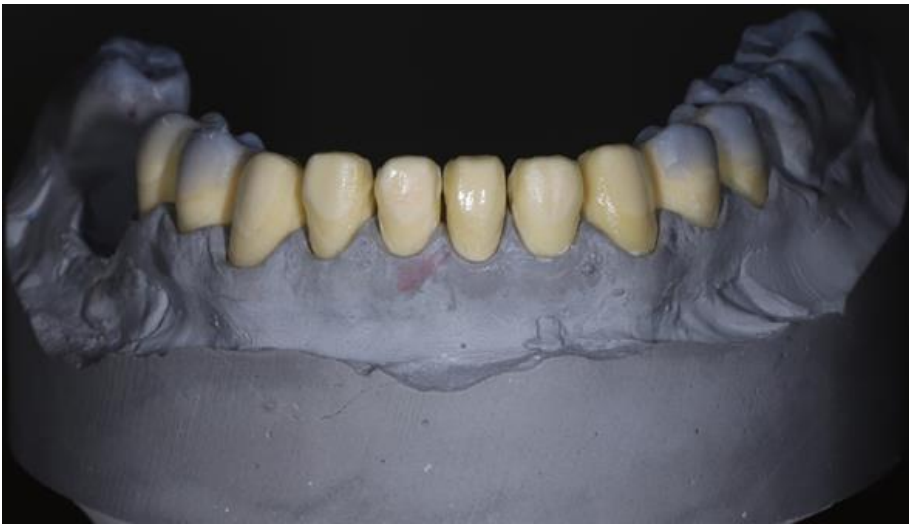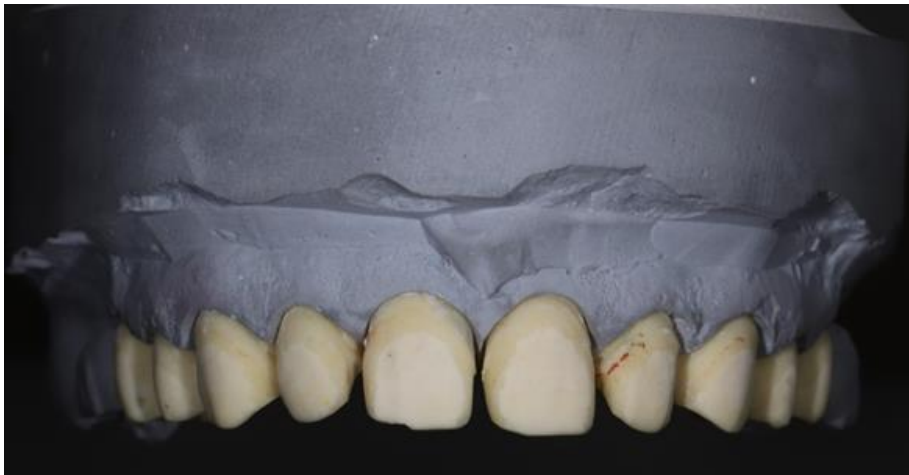**Printed casts with digital wax up**



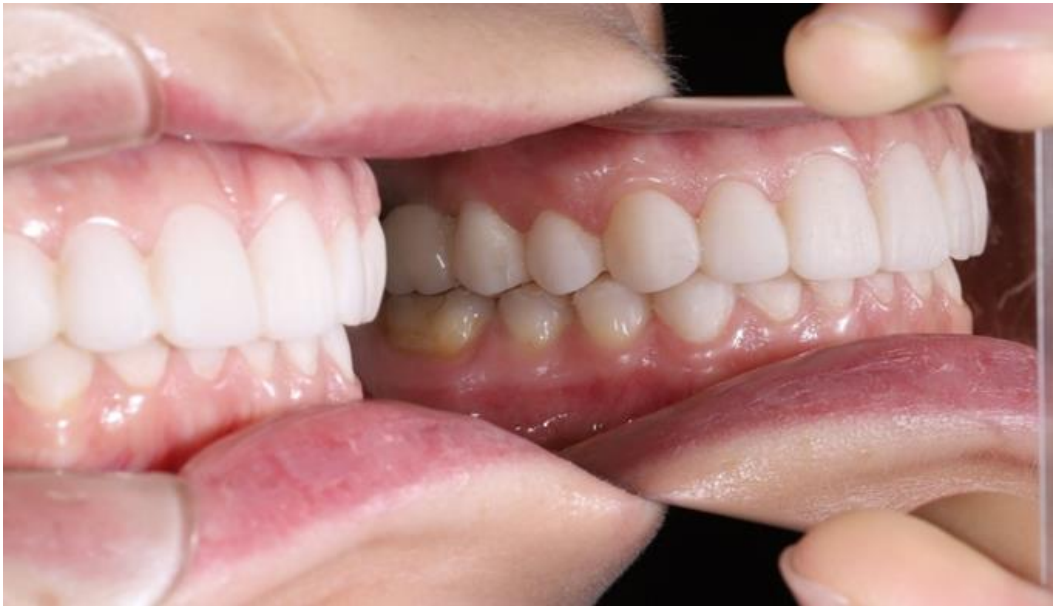
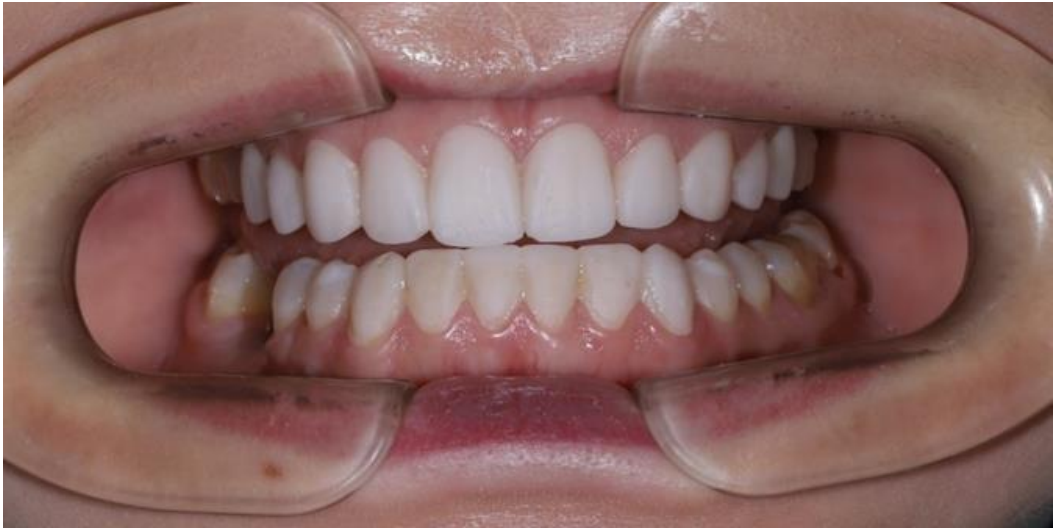
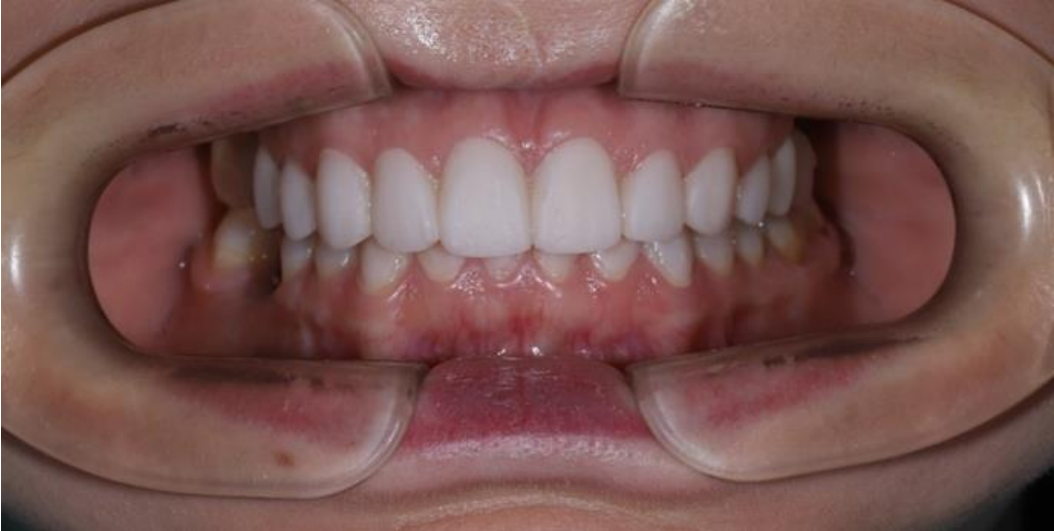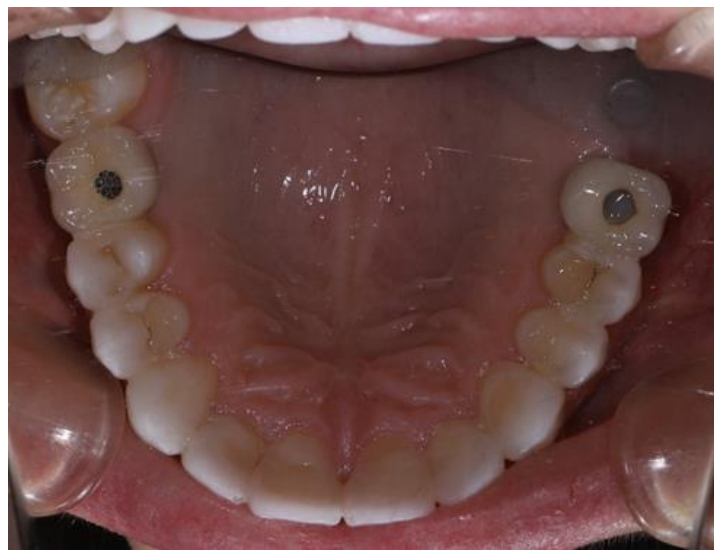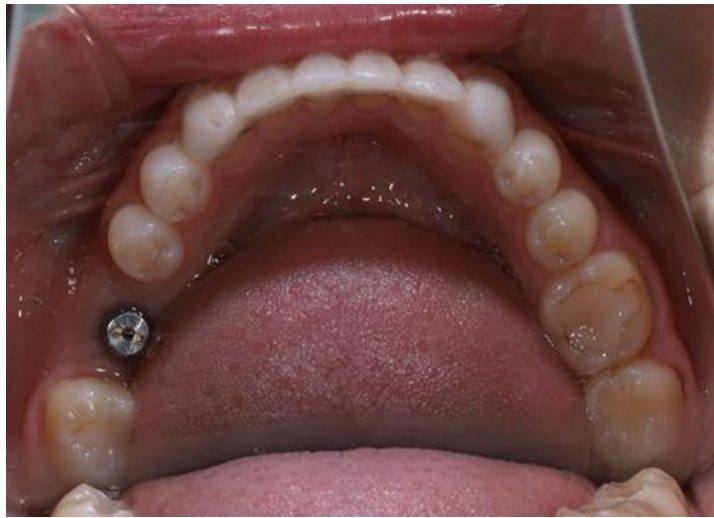RP



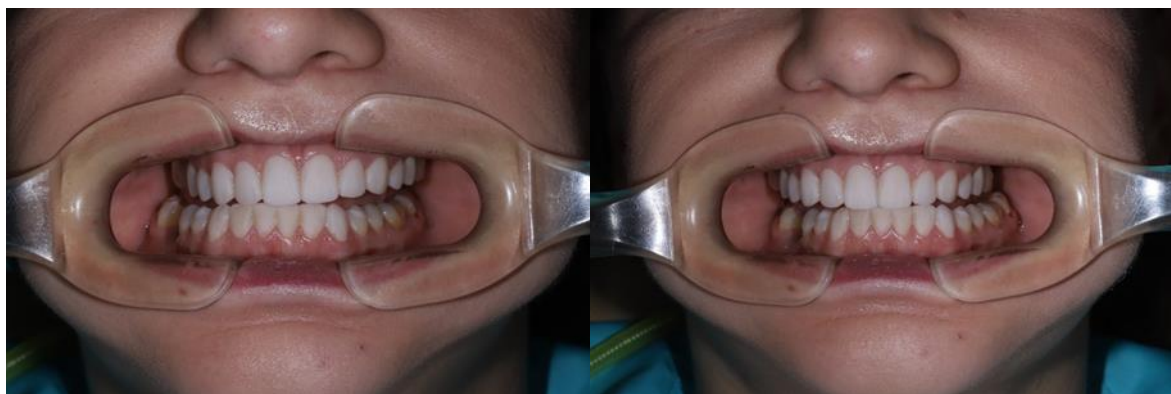

**Mock-up march 2023**

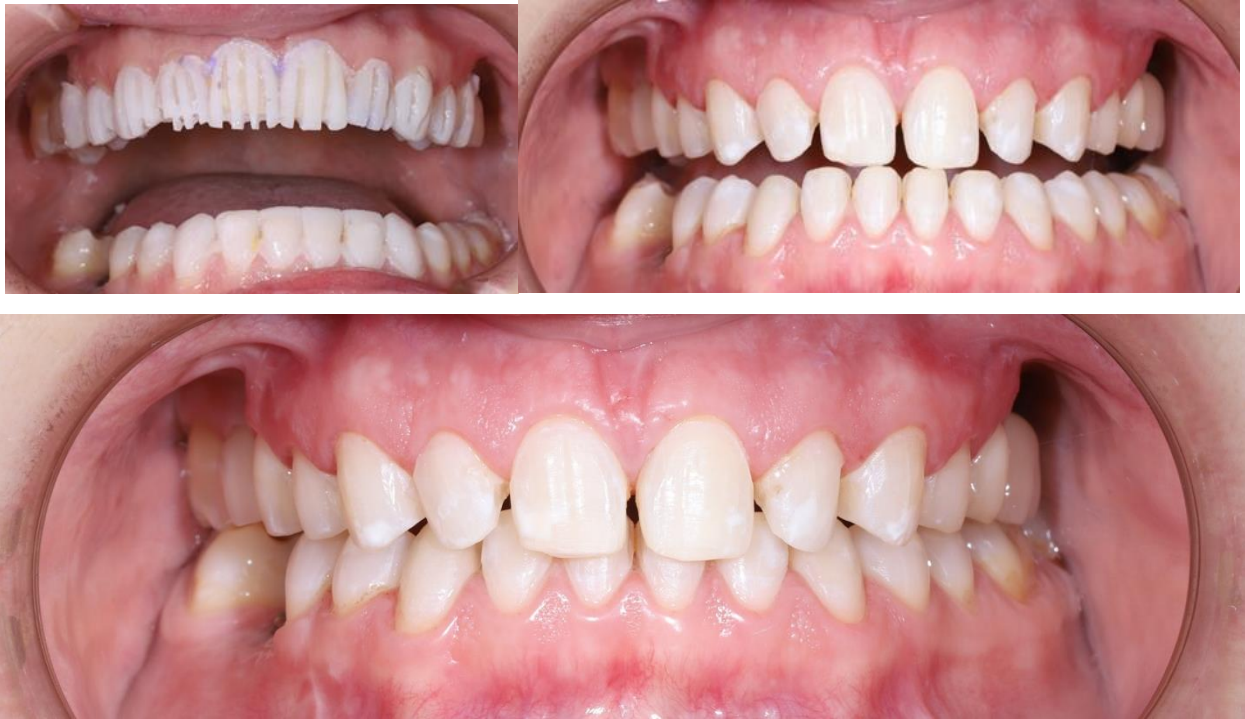



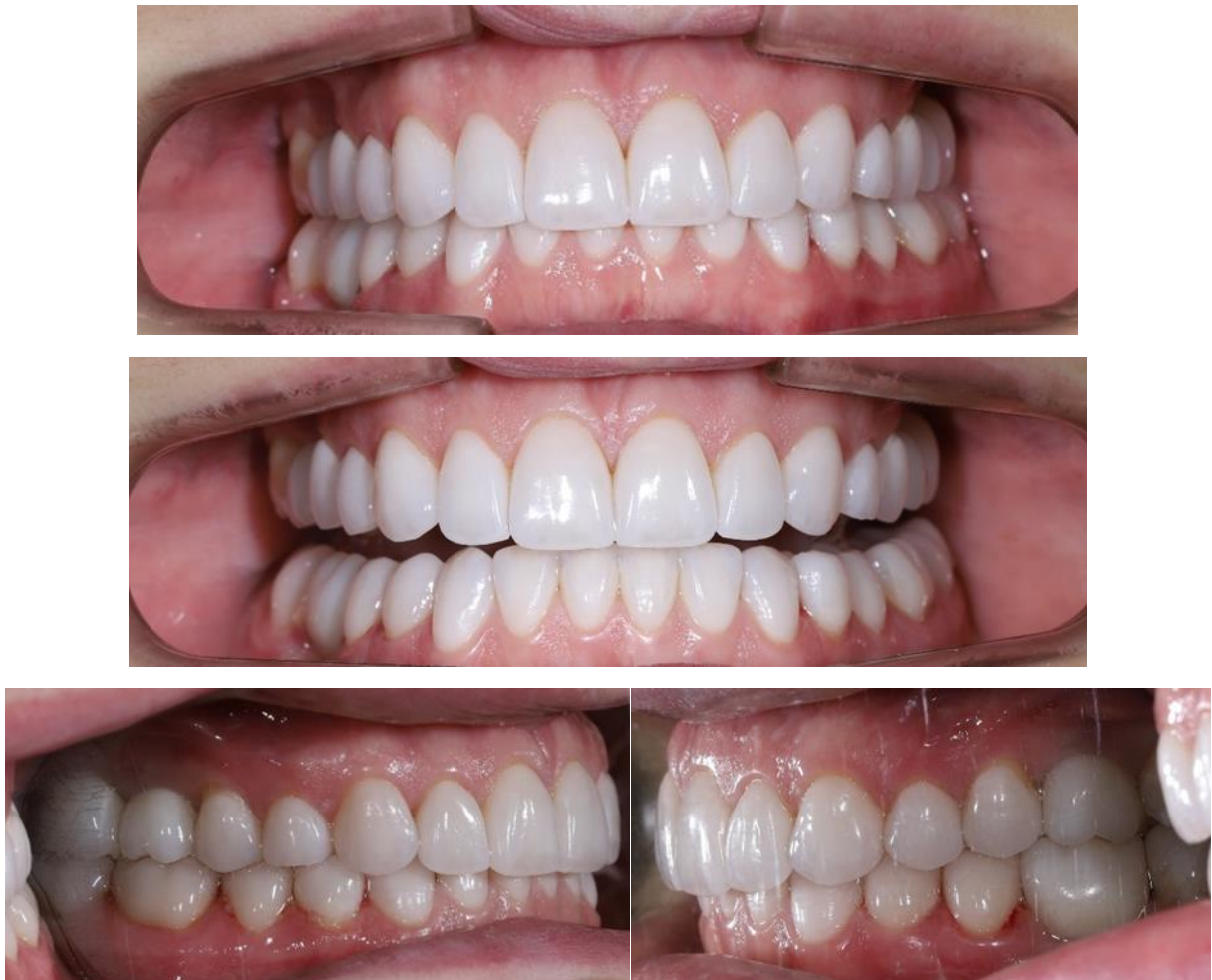**Canine guidance march 2023**

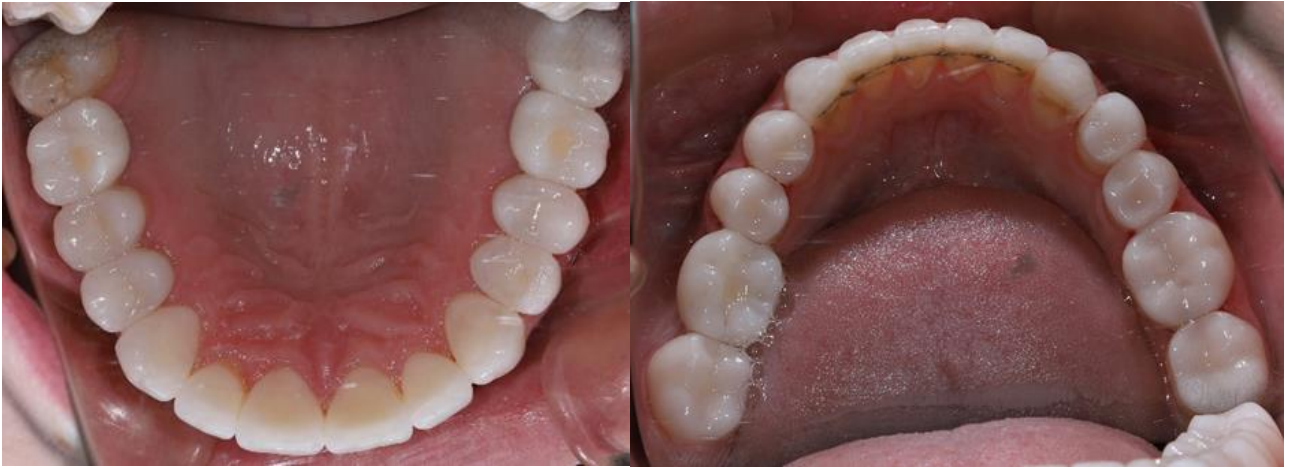

## Teeth Preparation March 2023



## Results: Final dental restorations





**Before / After**

